



## Additional slip of pectoralis major muscle — the costohumeralis

Published online March 18th, 2008 © <http://www.ijav.org>T. Ramesh RAO <sup>[1]</sup> ✦Prakashchandra SHETTY <sup>[2]</sup>Suresh RAO <sup>[3]</sup>

Department of Paraclinical Sciences, Faculty of Medical Sciences, The University of The West Indies, St. Augustine, Trinidad, WEST INDIES [1], Department of Anatomy, Kasturba Medical College, Manipal – 576104, Udupi, Karnataka, INDIA [2], Department of Preclinical Sciences, Faculty of Medical Sciences, The University of The West Indies, St. Augustine, Trinidad, WEST INDIES [3].



✦ T. Ramesh Rao, MSc, PhD  
Faculty of Medical Sciences  
Department of Paraclinical Sciences  
Faculty of Medical Sciences  
The University of The West Indies  
St. Augustine, Trinidad, WEST INDIES.  
☎ +1 (868) 662-1472, ext. 5001  
✉ +1 (868) 662-1472  
✉ varun1195@yahoo.com

Received November 28th, 2008; accepted March 18th, 2009

### ABSTRACT

We present a rare case of costohumeralis muscle, an accessory slip originating from the sixth rib near costochondral junction and running along the lower border of the pectoralis major muscle, inserting onto the medial epicondyle of the humerus on the right side. The occurrence of this costohumeralis muscle also showed a coincidental loss of the classical twisting of the tendinous insertion of the pectoralis major muscle, which proves that this muscle is variable in its development and attachment. Clinical considerations of such a variation include ulnar nerve entrapment and functionally limited abduction of humerus. © *IJAV*. 2009; 2: 35–37.

**Key words** [chondroepitrochlearis] [costoepitrochlearis] [costohumeralis] [medial epicondyle of humerus] [pectoralis major muscle]

### Introduction

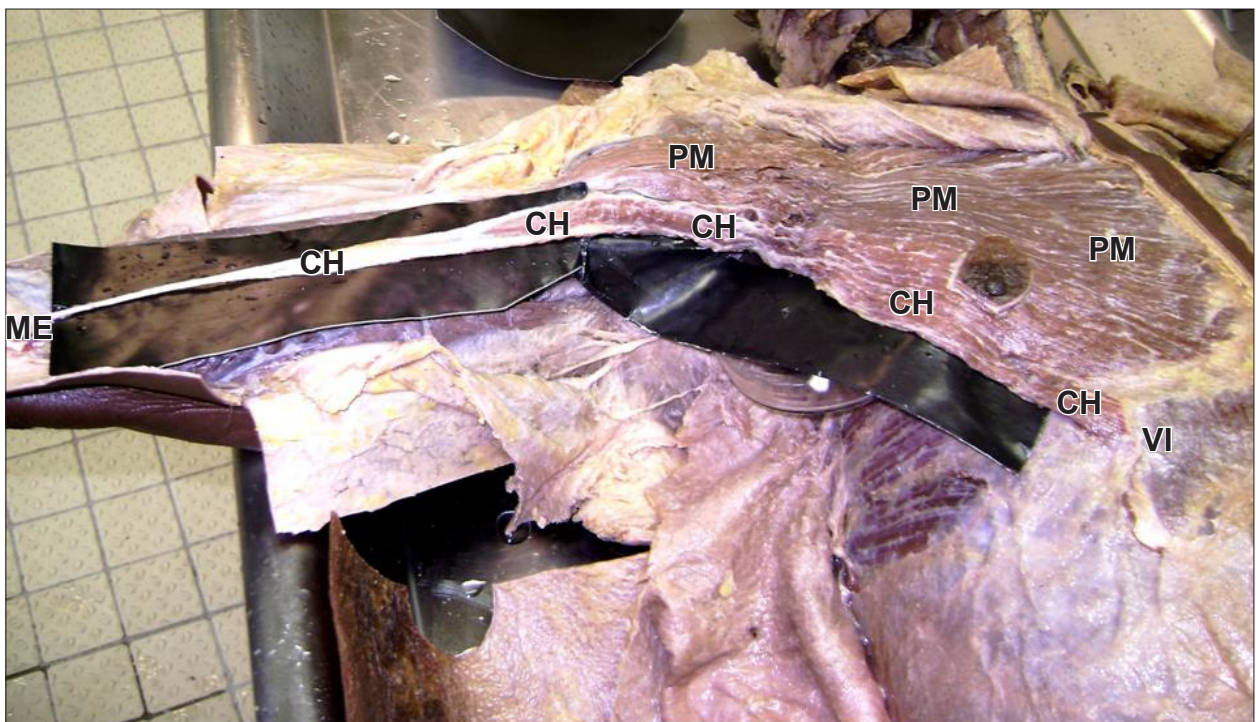
Variant muscles usually do not cause symptoms but are of academic interest. They may present as a surgical problem if they cause symptoms. It is difficult to accurately differentiate them from soft-tissue tumors. The chondroepitrochlearis, costoepitrochlearis or costohumeralis are rare muscular variations that may arise from the pectoralis major muscle, the costal cartilage, or the aponeurosis of the external oblique muscle, crossing the axilla, and inserting into the medial intermuscular septum or medial epicondyle of the humerus. In the present case, we found a variable muscular slip originating from the sixth rib near costochondral junction and running along the lower border of the pectoralis major muscle, inserting onto the medial epicondyle of the humerus on the right side. The muscle is variable in its attachment; such variants are of considerable morphological significance. It is analogous to extensions of the pectoralis major which occur normally in certain lower mammals. The occurrence of this costohumeralis muscle also showed a coincidental loss of the classical twisting of the tendinous insertion of the pectoralis major muscle.

### Case Report

Using conventional dissection techniques, the right upper limb of a 66-year-old, well-built, embalmed male cadaver is dissected with a purpose of preparation of the teaching and museum anatomical specimens. The medical history of this cadaver was not available. The

skin, superficial fascia and the deep fascia were removed systematically on both sides of the pectoral region and flexor compartment of the arm. Special attention was given to the origin and insertion of the costohumeralis muscle. Following the fine dissection, the costohumeralis muscle was photographed.

During dissections of the right upper limb, costohumeralis muscle on the right side. The costohumeralis originated as a muscular slip from the 6th rib near the costochondral junction to course along the lower border of the pectoralis major muscle. These costohumeralis muscle fibers close to the insertion of the pectoralis major coursed superficial to the brachial vessels and basilic vein, and inserted onto the medial epicondyle of the humerus. The following are the approximate measurements of the variant slip (costohumeralis) from its origin at the sixth rib to its insertion onto the medial epicondyle of the humerus; muscle length, 28 cm; tendon length, 16 cm; maximum muscle width, 1.7 cm; tendon width, 0.3 cm. The occurrence of this costohumeralis muscle also showed a coincidental loss of the normal twisting of the tendinous insertion of the pectoralis major muscle, which proves that this muscle was variable in its development and attachment (Figure 1). However, the left limb displayed the normal arrangement and attachments of pectoralis major muscle and the variable costohumeralis muscle was not present. We did not notice any signs of other diseases or pathological conditions during the dissection.



**Figure 1.** Dissection of the right upper limb showing the costohumeralis muscle. (*PM: pectoralis major muscle, CH: costohumeralis muscle, ME: medial epicondyle of humerus, VI: sixth rib*)

### Discussion

New imaging techniques, such as computed tomography and magnetic resonance imaging, made easier the detection of the muscle variations of the upper limb. These variations are important in defining the anatomical features in relation to clinical diagnosis and surgical procedures. The knowledge of the anatomical variations in the axilla is important in surgical interventions, considering the frequency of procedures done in this region. In considering variations, the muscle may be looked upon as composed of four portions – a clavicular, a sternal, a costal and an abdominal, the last being the portion that arises from the aponeurosis of the external oblique. These portions vary in the extent of their attachments and in the degree of separation that they present. The abdominal portion may extend to the umbilicus. This portion is considered to be a derivative of the pannicular muscle of the lower mammals. On the sternum the muscles of the two sides may decussate across the middle line. The sternocostal portions of the muscle are more frequently deficient or missing than the clavicular, but in rare cases the entire muscle is absent. The clavicular portion of the muscle may be fused with the deltoid. The sternocostal may extend laterally to the latissimus dorsi. There may be an intimate fusion of the abdominal portion with the rectus abdominis or external oblique. Sometimes a slip may run from the pectoralis major to the biceps, the pectoralis minor, coracoid process, joint capsule or brachial fascia [1], which normally seen in certain lower mammals [2].

The abdominal slip from the aponeurosis of the external oblique muscle may be sometimes absent. The numbers

of costal attachments and in the extent to which the clavicular and costal parts are separated may vary. Right and left muscles may decussate across the sternum. A superficial vertical slip, or slips, may ascend from the lower costal cartilages and rectus sheath to blend with sternocleidomastoid or to attach to the upper sternum or costal cartilages. This is the sternalis (rectus sternalis). Agenesis can result in the partial or complete absence of muscle [3].

The present case confirms the previous studies, which reported that a muscular slip, costoepectrochlearis, chondroepitrochlearis or chondrohumeralis, has been described arising from one or more ribs, crossing the axilla, and inserting into the medial intermuscular septum or onto the medial epicondyle of the humerus. It has been reported that in these cases the usual twist of the tendon of pectoralis major may fail to occur. The incidence of this type of cases is 12-20% [4].

Flaherty et al. reported the only example of a bilateral chondroepitrochlearis muscle associated with the bilateral absence of the axillary arch muscle and the absence of the normal twisted insertion of the pectoralis major muscle. Landry concluded that chondroepitrochlearis is an atavistic anomaly which demonstrates the distal extent of the insertion in ancestral forms. The chondroepitrochlearis muscle has been found at autopsy in infants with chromosomal defects, namely, trisomy 13 with a D/D translocation and trisomy 18. Barash et al. postulated that the genetic code for such atavistic muscles is normally repressed during embryogenesis and

that trisomy 18 causes derepression of these genetic loci [5].

Jaijesh reported the unilateral presence of the chondroepitrochlearis muscle, with absence of normal twisted insertion of the pectoralis major muscle [6]. This is supported by Vijay Paul et al., who also reported the blood supply and nerve to this variant muscle [7]. The arterial supply to the chondroepitrochlearis muscle was from the lateral thoracic artery and the nerve supply was through a branch of the medial pectoral nerve.

Loukas et al. presented a rare case of an accessory muscular slip originating from the pectoralis major and inserting onto the medial epicondyle of the humerus and medial brachial intermuscular septum. They proposed a new nomenclature for this variant slip as

thoracoepicondylaris. According to the authors this term more accurately reflects the origin and insertion of this variant muscular slip [8].

Pectoral groups of muscles show a special degree of variability, not only in the extent and character of the attachments of the muscles, but in the presence of a great variety of separate aberrant slips which are occasionally present. It will be recollected that the pectoral group of muscles arises from a common rudiment at the base of the limb bud. The anomaly has attracted clinical attention because of its potential to cause cosmetic defects, to restrict abduction of the arm, and to entrap the ulnar nerve. Thus, it may be of particular interest to plastic and orthopedic surgeons, and neurologists.

## References

- [1] Anson BJ, Morris' Human Anatomy. 12th Ed., New York, McGraw-Hill. 1966; 478–479.
- [2] Schafer ES, Symington J, Bryce TH. Quain's Element of Anatomy; Myology, Volume IV, Part II. London, Longmans, Green, and Co. 1923; 99–104.
- [3] Standring S, ed. Gray's Anatomy. The Anatomical Basis of clinical practice. 39th Ed., Edinburgh, Churchill & Livingstone. 2005; 833–835.
- [4] Bergman RA, Thomson SA, Afifi AK, Saadeh FA. Compendium of Human Anatomic Variation. Baltimore, Urban & Schwarzenberg. 1988; 7–8.
- [5] Flaherty G, O'Neill MN, Folan-Curran J. Case report: bilateral occurrence of a chondroepitrochlearis muscle. *J Anat.* 1999; 194: 313–315.
- [6] Jaijesh P. Unilateral appearance of a chondro-epitrochlearis muscle-a case report. *Indian J Plast Surg.* 2005; 38: 164–166.
- [7] Samuel VP, Vollala VR. Unusual pectoralis major muscle: the chondroepitrochlearis. *Anat Sci Int.* 2008; 83: 277–279.
- [8] Loukas M, Louis RG Jr, Kwiatkowska M. Chondroepitrochlearis muscle, a case report and a suggested revision of the current nomenclature. *Surg Radiol Anat.* 2005; 27: 354–356.