



## Median nerve and brachial artery entrapment in the tendinous arch of coracobrachialis muscle

Published online November 28th, 2008 © <http://www.ijav.org>

Vincent RODRIGUES ✦  
 Satheesha NAYAK  
 Somayaji NAGABHOOSHANA  
 Venkata Ramana VOLLALA

Melaka Manipal Medical College (Manipal Campus), International Centre for Health Sciences, Manipal, Karnataka State, INDIA.



✦ Dr. Vincent Rodrigues, MSc, PhD  
 Associate Professor of Anatomy  
 Melaka Manipal Medical College (Manipal Campus)  
 International Centre for Health Sciences  
 Madhav Nagar, Manipal  
 Udipi District  
 Karnataka State, 576 104, INDIA.  
 ☎ +91 820 2922519  
 📠 +91 820 2571905  
 ✉ [vincentanatomy@yahoo.com](mailto:vincentanatomy@yahoo.com)

Received August 21st, 2008; accepted November 1st, 2008

### ABSTRACT

Knowledge of variation in the pattern of muscle insertion and possible neurovascular entrapment is important for orthopedic surgeons, plastic surgeons and physiotherapists. We found a variation in the insertion pattern of coracobrachialis and entrapped median nerve and brachial artery by the tendinous arch of the muscle, in relation to the neurovascular bundle. The coracobrachialis had an additional insertion in the form of a tendinous arch which extended from the lower part of the muscle to the medial intermuscular septum. The median nerve, brachial artery, its venae comitantes and a muscular branch from brachial artery passed deep to this arch. The abnormality reported here might result in neurovascular compression symptoms in upper limb. © IJAV. 2008; 1: 28–29.

**Key words** [brachial artery] [coracobrachialis] [median nerve]

### Introduction

Coracobrachialis is a weak muscle of the anterior compartment of the arm. The muscle takes origin from the tip of the coracoid process in common with the short head of the biceps brachii. It is inserted to the middle 5 cm of the medial border of the humerus. The muscle is pierced by musculocutaneous nerve and is supplied by the same nerve. It is a weak flexor of the arm.

The brachial artery is a continuation of the axillary artery and is superficial throughout its course in the arm. When it enters the cubital fossa it lies anterior to brachialis and lateral to median nerve. At the cubital fossa it is crossed by the bicipital aponeurosis which separates the artery from the median cubital vein. The brachial artery terminates by dividing into radial and ulnar arteries at the level of the neck of the radius.

The median nerve is formed by its medial root and lateral root coming from medial and lateral cords of brachial plexus respectively. It descends along the lateral side of the third part of axillary artery and proximal part of brachial artery. At the middle of the arm opposite the insertion of coracobrachialis the nerve crosses from lateral to medial, usually in front of the artery and then accompanies along the medial side of the brachial artery. It appears in the cubital fossa beneath the bicipital aponeurosis and rests on the brachialis. The nerve leaves the cubital fossa through a gap between the superficial and deep heads of pronator teres.

We noted a variation of insertion of coracobrachialis and course of median nerve and brachial artery in the right upper limb.

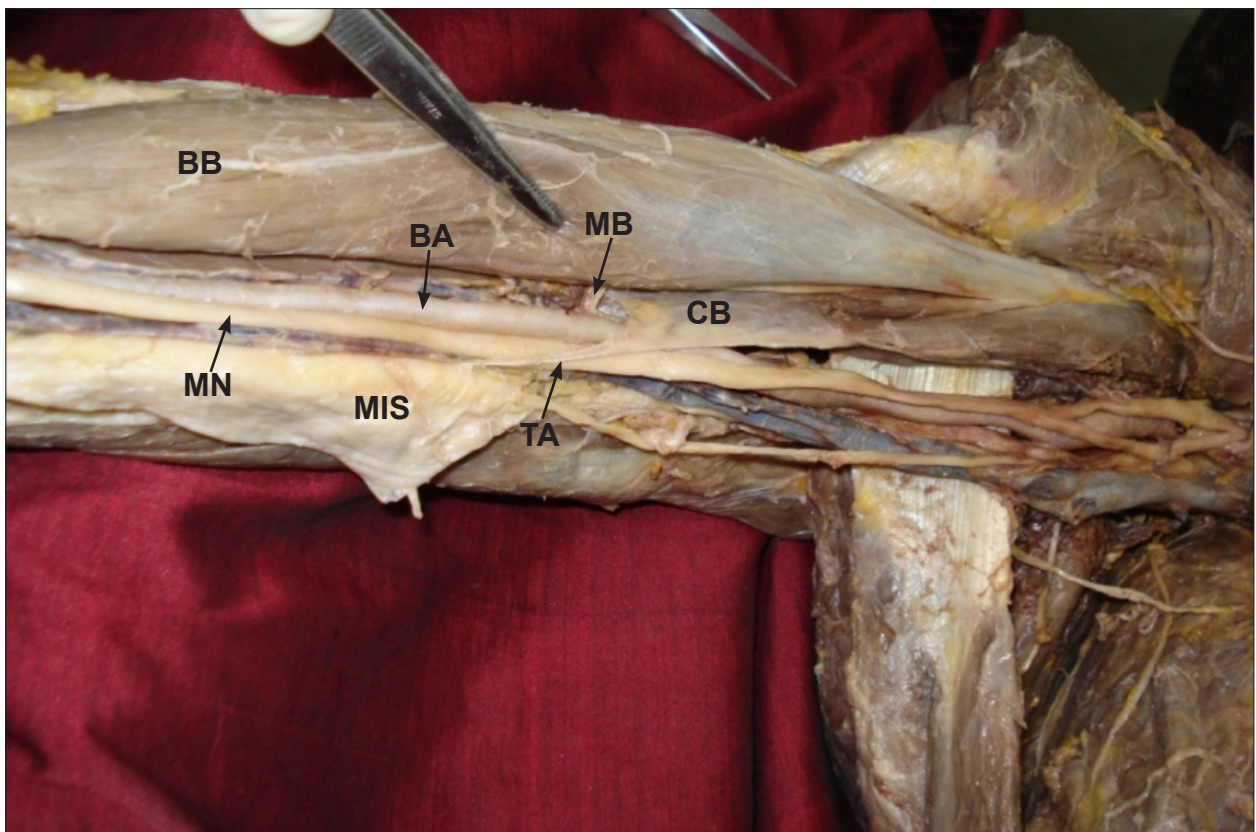
### Case Report

During routine dissections for medical undergraduates, a few variations were found in the anterior compartment of the arm, of an approximately 45 year old female cadaver. The variations found in the right limb and were unilateral. The coracobrachialis muscle had an aponeurosis in its lower part. This aponeurosis formed a tendinous arch around the median nerve and brachial artery and got inserted to the medial intermuscular septum (Figure 1). A muscular branch from brachial artery to the biceps and the venae comitantes of brachial artery also passed deep to the aponeurotic arch. There were no other abnormalities in the arm.

### Discussion

The coracobrachialis muscle can have variations in its origin, insertion and nerve supply. It may be absent or may even get inserted to the shoulder joint capsule. According to Bergman et al., [1] the coracobrachialis might fuse with pectoralis major, brachialis or latissimus dorsi. Accessory heads of coracobrachialis have been reported previously by numerous researchers [2–4].

There are three well explained entrapment syndromes involving median nerve or its branches, namely carpal tunnel syndrome, pronator teres syndrome and anterior interosseous syndrome. The literature survey revealed



**Figure 1.** Dissection of the right upper limb showing abnormal course of the median nerve and brachial artery. (MN: median nerve, BA: brachial artery, MB: muscular branch of brachial artery, BB: biceps brachii, MIS: medial intermuscular septum, TA: tendinous arch of coracobrachialis, CB: coracobrachialis tendon)

the possible median nerve entrapment due to a third head of biceps brachii [5,6]. Even though anatomy literature hardly mentions the median nerve compression due to bicipital aponeurosis, a few research reports say that it could be a cause of high median nerve compression, along with brachial artery [7]. Median nerve and brachial artery may rarely be compressed by coracobrachialis. A recent report describes the variable insertion of coracobrachialis into the distal medial border of the humerus and the

possibility of compression of median nerve and brachial artery [8].

The insertion of coracobrachialis in the form of a tendinous arch into the medial intermuscular septum has not been reported previously. Since the median nerve and brachial artery passed deep to the arch, there is a possibility of their compression by the aponeurotic arch. This might in turn result in neuro-vascular compression symptoms in the forearm and hand.

## References

- [1] Bergman RA, Afifi AK, Miyauchi R. Coracobrachialis. <http://www.anatomyatlases.org/AnatomicVariants/MuscularSystem/Text/C/31Coracobrachialis.shtml> (accessed May 2008).
- [2] Koguz C, Içten N, Yildirim M. A rare accessory coracobrachialis muscle: a review of the literature. *Surg. Radiol. Anat.* 2003; 24: 406–410.
- [3] El-Naggar MM, Zahir FI. Two bellies of the coracobrachialis muscle associated with a third head of the biceps brachii muscle. *Clin. Anat.* 2001; 14: 379–382.
- [4] Jakubowicz M, Ratajczak W. Variation in morphology of the biceps brachii and coracobrachialis muscles associated with abnormal course of blood vessels and nerves. *Folia Morphol. (Warsz)*. 2000; 58: 255–258.
- [5] Paval J. A rare case of possible median nerve entrapment. *Neuroanatomy*. 2006; 5: 35–36.
- [6] Mas N, Pellin C, Zagyan R, Bahar H. Unusual relation of the median nerve with the accessory head of the biceps brachii muscle: An original case report. *Int. J. Morphol.* 2006; 24: 561–564.
- [7] Kumar H, Das S, Gaur S. Entrapment of the median nerve and the brachial artery by lacertus fibrosis. *Arch. Med. Sci.* 2007; 3: 284–286.
- [8] El-Naggar MM, Al-Sagoff S. Variant of the coracobrachialis muscle with a tunnel for the median nerve and brachial artery. *Clin. Anat.* 2004; 17: 139–143. 692–695.