

Annual Congress on
**Rehabilitation
and Future Pharma**

November 17, 2022 | Webinar

Keynote Forum



Annual Congress on
Rehabilitation and Future Pharma

November 17, 2022 | Webinar

Received date: 07-07-2022 | Accepted date: 08-07-2022 | Published date: 26-12-2022



Liliann Abarza

Universidad de la Frontera, Chile

Determination of morphogeometric patterns in individuals with total mandibular edentulism in the interforaminal region from Cone Beam Computed Tomography (CBCTs): Pilot study

The aim of this study was to determine the morphogeometric patterns of the interforaminal region from Cone Beam Computed Tomography (CBCT) scans of individuals with total mandibular edentulism. CBCT images were obtained from 40 patients with total edentulism who are older (12 men and 28 women; average age of 69.5 9.4 years) and who wore a non-implant-supported, lower, removable, total prosthesis. We conducted a two-dimensional (2D) morphogeometric analysis of the Digital Imaging and Communication in Medicine (DICOM) files from the CBCT scans, and five equidistant cross sections were planned. For the three-dimensional (3D) morphogeometric analysis, Standard Triangular Language (STL) files were obtained after segmentation of the interforaminal mandibular region, and four anatomical landmarks and their respective curves were digitized. The patterns among the shapes were determined using Principal Component Analysis (PCA) on MorphoJ software (version 1.07a). The results of the 2D morphogeometric analyses for PCA of the interforaminal mandibular paramedian region were PC1 or elongated drop shape, 54.78%; PC2 or wineskin shape, 17.65%; PC3 or pear shape, 11.77%; and PC4 or eggplant shape, 5.71%, and those for PCA of the symphyseal region were PC1 or elongated drop shape, 62.13%; PC2 or ovoid shape, 11.64%; PC3 or triangular shape, 9.71%; and PC4 or tuber shape, 4.96%. The results of the 3D morphogeometric analyses for the interforaminal hemi mandibular region were PC1, 59.83%; PC2, 10.39%; PC3, 7.67%; and PC4, 5.09%. This study provides relevant information for future clinical guidelines on prosthetics and implants, in addition to proposing the use of new technologies that support diagnosis and treatment in patients with edentulism.

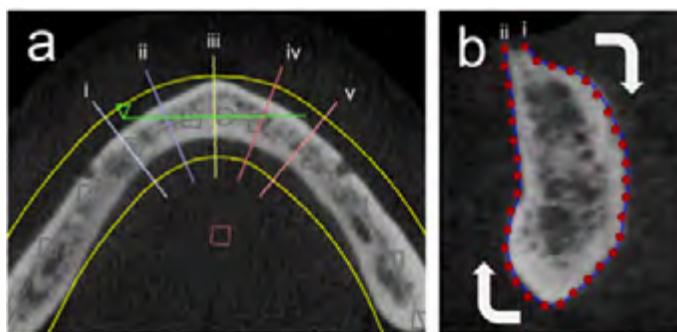


Figure 1: Two-dimensional digitization. (a) Interforaminal cross sections in the axial view for (i, ii, iv, v) paramedian sections and (iii) a symphysis section. (b) Curve digitization in tpsDig; (i) starting point and (ii) end point.

Annual Congress on **Rehabilitation and Future Pharma**

November 17, 2022 | Webinar

Recent Publications

1. Abarza Arellano, Liliann, Sandoval Vidal, Paulo, & Flores Velásquez, Marco. (2016). Registro interoclusal digital en rehabilitación oral: «Sistema T-Scan® III»: Revisión bibliográfica. Revista clínica de periodoncia, implantología y rehabilitación oral, 9(2), 95-101.
2. Abarza L, Acuña-Mardones P, Sanzana-Luengo C, Beltrán V. Determination of Morphogeometric Patterns in Individuals with Total Mandibular Edentulism in the Interforaminal Region from Cone Beam Computed Tomography (CBCT) Scans: A Pilot Study. Applied Sciences. 2022; 12(8):3813.
3. Sanzana-Luengo C, Díaz L, Abarza L, Alvarado E & Beltrán V. Teledentistry protocol for the elderly in the context of the COVID-19 pandemic through a web platform/mobile app: approach from the general dentist. J Oral Res 2022; S-1 (Seminario Científico):1-8. Doi:10.17126/joralres.2022.026.

Biography

Liliann Abarza is an undergraduate and postgraduate professor at Dental School, Universidad de la Frontera Temuco, Chile. Her objective is to provide the use of new digital flows for the benefit of the adult population and older adults to develop prosthetic implant planning guidelines according to morphogeometric patterns.

lilian.abarza@ufrontera.cl