

CASE REPORT

A case of ancient schwannoma of arm with profuse vascularity

Ajaya Kumar¹, Anju Mohan², Geetha Gopal³

Kumar A. A case of ancient schwannoma of arm with profuse vascularity. *J Neuropathol.* 2023; 3(1):1-3.

ABSTRACT

A 70-year old female had right arm swelling of 10 years duration, of 5 cm size, and with prominent vessels. She had sphenoid tumor earlier, underwent transnasal decompression and it was diagnosed as ossifying fibroma. Contrast enhanced magnetic resonance imaging showed a cystic swelling with thick peripheral enhancement, abutting the brachial artery. The differential diagnoses were soft tissue sarcoma, hemangioma, and schwannoma. Excision was done en toto, after cauterising the arterioles around.

Histopathology report came as ancient schwannoma. S100 was positive.

This is a report of an ancient schwannoma of arm with profuse vascularity. The histopathological findings showed congested blood vessels in addition to the features of ancient schwannoma. The theory for degeneration in ancient schwannoma is 'the insufficiency of vascular supply during the growth of the tumor'. But in this case there were lots of vessels.

Key Words: Nerve Sheath Neoplasms; Neurilemmoma; Cysts; Sarcoma; Magnetic Resonance Imaging; S 100 protein.

INTRODUCTION

Ancient schwannomas are long standing tumors with degenerative changes such as cystic necrosis, hemorrhage, xanthomatous change, fibrosis, perivascular hyalinization, calcification and nuclear pleomorphism. The currently understood reason for degeneration in ancient schwannoma is the insufficiency of vascular supply during the growth of the tumor. This is a report of an ancient schwannoma of arm with profuse vascularity. The histopathological findings showed congested blood vessels in addition to the features of ancient schwannoma. The patient had ossifying fibroma of sphenoid also, which may be an association.

CASE PRESENTATION

A 70-year old female had right arm swelling of more than 10 years duration. There was recent increase in size. She had sphenoid tumor earlier. It compressed the left optic nerve. There was mild enhancement in Contrast Enhanced Magnetic Resonance Imaging (CEMRI). Transnasal decompression was done. The Histopathological Report (HPR) was ossifying fibroma. On examination of the arm swelling, the size was 5 cm × 5 cm. It was located superior and medial to the cubital fossa. It was a soft and fluctuant swelling. There were dilated veins over the swelling. It was nonpulsatile. The pulsation of brachial artery was felt separately. The mobility was slightly restricted. There were no distal neurological

deficits. There was another small (1 cm), pedunculated, and firm swelling on the dorsum of the same elbow.

CEMRI showed a cystic swelling, in the subcutaneous plane abutting the biceps and the brachial artery (Figure 1a). There was thick peripheral enhancement with gadolinium (Figure 1b). The brachial artery was displaced. The differential diagnoses were soft tissue sarcoma, hemangioma, and schwannoma.

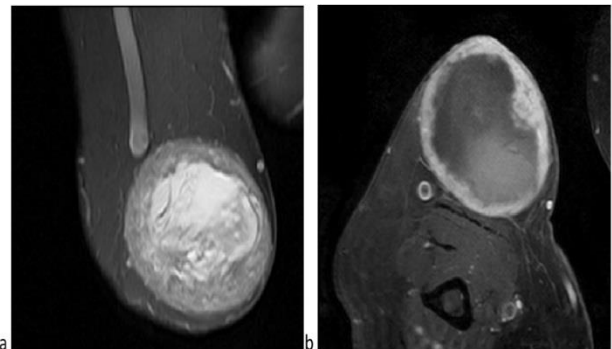


Figure 1 a) MRI showing cystic swelling; **b)** Contrast enhanced MRI showing thick peripheral enhancement

The swelling was excised under supraclavicular block. A curved incision was made medially over the swelling, and the dissection was done through the subcutaneous plane. The arterioles and venules into

¹Senior Consultant Neurosurgeon, Muthoot hospital, Kozhencherry, Pathanamthitta, India, ²Fellow in Oncopathology, Consultant pathologist Muthoot hospital, Kozhencherry, Pathanamthitta. Kerala, India, ³Senior consultant pathologist, Muthoot hospital, Kozhencherry, Pathanamthitta. Kerala, India.

Correspondence: Ajaya Kumar, Senior Consultant Neurosurgeon, Muthoot hospital, Kozhencherry, Pathanamthitta, India. Telephone: 914682314000, e-mail: drajayakumara@gmail.com

Received: 27-November-2022, Manuscript No. PULNP-22-5867; Editor assigned: 12-December-2022, Pre QC No. PULNP-22-5867 (PQ); Reviewed: 18-December-2022, QC No. PULNP-22-5867 (Q); Revised: 20-December-2022, Manuscript No. PULNP-22-5867 (R); Published: 28-January-2023, doi:10.37532/pulnp.2023.3(1).1-3



This open-access article is distributed under the terms of the Creative Commons Attribution Non-Commercial License [CC BY-NC] [<http://creativecommons.org/licenses/by-nc/4.0/>], which permits reuse, distribution and reproduction of the article, provided that the original work is properly cited and the reuse is restricted to noncommercial purposes. For commercial reuse, contact reprints@pulsus.com

the tumor were cauterized and cut. The aspiration of the swelling yielded hemorrhagic fluid. It was excised in Figure 2.

The small swelling on the dorsum of elbow also was excised. The postoperative period was uneventful. Neurovascular examination was within normal limits. She had mild swelling of the wound which subsided.

The histopathological examination showed an encapsulated nodular mass, with congested blood vessels, cystic spaces, central hemorrhage and necrosis (Figure 3a). The capsule was compressed and fibrous. The cells were of spindle shape. The cells had fibrillary cytoplasm and oval vesicular nuclei. There were hemorrhage, congestion, cystic changes, and myxoid changes. Immunohistochemistry showed S 100 positivity (Figure 3b). Ki 67 was 1%-3%, suggestive of low index (Figure 3c). The findings were suggestive of ancient schwannoma. The HPR of the small swelling was a neurofibroma.

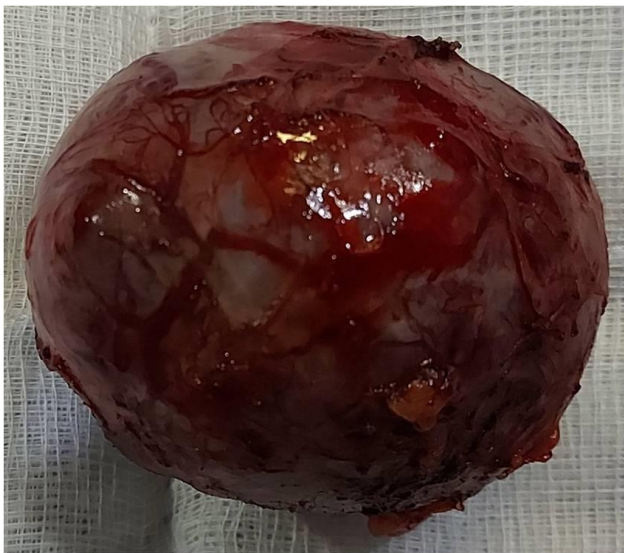


Figure 2) Sphenoid tumor

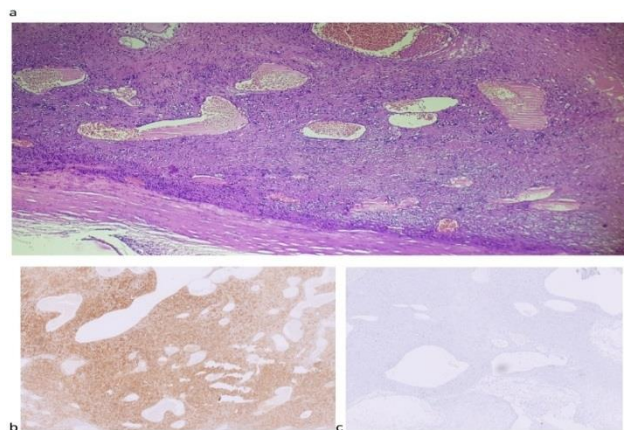


Figure 3a) Histopathological examination showing spindle cells, hemorrhage, congestion, and cystic, and myxoid changes; b) Immunohistochemistry positive for S 100; c) Ki 67 low index.

DISCUSSION

Ackerman and Taylor described ancient schwannomas which are long standing tumors with degenerative changes [1]. They described that 10 out of 48 neurogenic tumours of the thorax had hypocellular areas within hyalinised matrices. They attributed the degenerative changes

to the long duration and coined the term 'ancient schwannoma'. The reason behind the degeneration is supposed to be the insufficiency of vascular supply during the growth of the tumor [2].

Ancient schwannomas have been reported in median nerve, ulnar nerve, radial nerve, hand, thumb, sciatic nerve, lateral cutaneous nerve of thigh, tibial nerve, sural nerve, and planar digital nerve[3]. The other areas where these can be seen are head and neck, thorax, retroperitoneum, and pelvis [4]. The features in CEMRI are heterogeneous intensity, cystic changes, and peripheral enhancement. The differential diagnoses are sarcoma and malignant peripheral nerve sheath tumor [5,6].

The histological features of ancient schwannoma described are those of schwannoma with degenerative changes and mild nuclear atypia and pleomorphism in addition. These are: diffuse hypocellular areas, loss of Antoni type A areas, accumulation of hyaline material, perivascular hyalinization, fibrosis, calcification, cystic necrosis, haemorrhage, xanthomatous change, myxomatous degeneration, infiltration by siderophages and histiocytes, nuclear atypia, pleomorphism, and nuclear palisading. Immunostaining for S 100 protein suggests a neural origin.

The peculiarity of the case is that there were many dilated vessels over the swelling. The theory for degeneration in ancient schwannoma is 'the insufficiency of vascular supply during the growth of the tumor'. But in this case there were lots of vessels. The difference in surgical steps from the reported cases was that the multiple arterioles and venules had to be cauterised because of the high vascularity. The histology showed congested blood vessels in addition to the usual features of ancient schwannoma. She had ossifying fibroma of sphenoid also. There are reports of association of Neurofibromatosis 1 (NF 1) with ossifying fibroma of skull and maxilla [7,8].

CONCLUSION

The differential diagnoses were soft tissue sarcoma, hemangioma, and schwannoma. Excision was done en toto, after cauterising the arterioles around. Histopathology report came as ancient schwannoma. S100 was positive.

REFERENCES

1. LV A. Neurogenous tumors within the thorax; a clinicopathological evaluation of forty-eight cases. *Cancer*. 1951;4(4):669-91.
2. Vilanova JR, Burgos-Bretones JJ, Alvarez JA, et al. Benign schwannomas: a histopathological and morphometric study. *J Pathol*. 1982;137(4):281-86.
3. Malizos K, Ioannou M, Kontogeorgakos V. Ancient schwannoma involving the median nerve: a case report and review of the literature. *Strateg Trauma Limb Reconstr*. 2013;8(1):63-6.
4. Matsumine H, Takeuchi M. Ancient schwannoma of the thumb pulp. *Plast Reconstr Surg Glob Open*. 2015;3(1).

5. Bhat AK, Acharya AM, Narayanakurup JK, et al. Ancient schwannoma of radial nerve: a report of two cases. *J Hand Surg.* 2017;22(04):526-30.
6. Vlychou M, Dailiana ZH. Ancient schwannoma of the hand. *J hand surg.* 2011;36(12):2030-33.
7. Ruggieri M, Pavone V, Tiné A, et al. Ossifying fibroma of the skull in a patient with neurofibromatosis type 1: Case report. *J neurosurg.* 1996;85(5):941-44.
8. Jendi SK, Khatib S, Mistry J, et al. Ossifying Fibroma of Maxilla in a Female Affected by Neurofibromatosis Type 1. *Indian J Otolaryngol Head Neck Surg.* 2019;71(3):2087-90.