

A new method in the treatment of postburn and post-traumatic scar contractures: Double-opposing Z- and V- (K-M-N) plasty

Ilteris Murat Emsen MD

IM Emsen. A new method in the treatment of postburn and post-traumatic scar contractures: Double-opposing Z- and V- (K-M-N) plasty. *Can J Plast Surg* 2010;18(2):e20-e26.

BACKGROUND: To date, many techniques for the surgical treatment of postburn scar contractures have been described. Some of the most popular techniques are Z-plasty, V-Y-plasty and their analogues. A major limitation of these techniques is that the excess tissue requires excision of the dog ear. The current study presents a new modification of the double-opposing Z- and V-plasty, called 'K-M-N plasty'.

METHODS: Twenty postburn scar contractures were successfully treated with K-M-N plasty. The postoperative results depict the versatility of this technique in the surgical treatment of postburn scar contractures, especially in the upper and lower extremities.

RESULTS: There was no distal flap necrosis, and postoperative recovery was uneventful in all operated patients. K-M-N plasty is an effective and alternative method for the surgical treatment of postburn scar contractures. In addition, drawing and flap transpositions were not complicated.

DISCUSSION: There are many advantages to using this technique: K-M-N plasty can be safely used when skin tension crosses the contracture line; it is superior to other local flaps because of its rich vascularity and mobility for superficial scars; it can be recommended to the inexperienced surgeon because it can be performed with ease; it is also an effective procedure for the pericontracture area due to its V limb (it can prevent recontracture); the colour and texture matches are more cosmetically acceptable, and the resultant contracture release is similar to other techniques; the dog ear formation is not seen; it can be performed under local anesthesia in most cases (not in children); and it has a shorter period of operation and hospitalization than other techniques.

Key Words: K-M-N plasty; Postburn scar contracture; V-Y-plasty; Z-plasty

Scar contractures and their treatment modalities are still a big problem for plastic and burn surgeons; there is no radical treatment for scar contractures yet. Scar tissue does not grow proportionately as we age, resulting in visible contractures and areas prone to recurrent scar formation. Z-plasty or multiple Z-plasties, W-plasty, V-Y-plasty, local distance flaps and skin grafts are frequently used. Another frequent technique in Z-plasty is using a 45° angle. Suzuki et al (1) suggested that the appropriate design for Z-plasty (modified planimetric Z-plasties, various V-Y-plasties or W-plasty) must be selected based on the scar location and the degree of contracture; surgeons can choose from a wide range of treatment options and many variations of Z-plasty. Suzuki et al (1) also proposed different classifications of V-Y-plasty, Y-V-plasty and its analogues, such as V-M-plasty, V-W-plasty, five-flap Z-plasty, seven-flap Z-plasty and its modifications (2). Often, the excess

Une nouvelle méthode pour le traitement des contractures cicatricielles après des brûlures ou des traumatismes : La double plastie en Z et en V opposés (K-M-N)

HISTORIQUE : Jusqu'à présent, de nombreuses techniques ont été décrites pour le traitement chirurgical des contractures cicatricielles après des brûlures. Parmi les plus populaires, on remarque la plastie en Z, la plastie en V et en Y et leurs analogues. Ces techniques comportent toutefois une limite importante : il faut exciser les tissus excédentaires aux extrémités. La présente étude expose une nouvelle modification de la double plastie en Z et en V opposés, la plastie en « K-M-N ».

MÉTHODOLOGIE : Vingt contractures cicatricielles après des brûlures ont été traitées avec succès au moyen de la plastie en K-M-N. Les résultats postopératoires démontrent la polyvalence de cette technique pour le traitement chirurgical des contractures cicatricielles après des brûlures, notamment des membres supérieurs et inférieurs.

RÉSULTATS : Il n'y avait pas de nécrose du lambeau distal, et la convalescence postopératoire s'est révélée sans histoire chez tous les patients opérés. La plastie en K-M-N est une nouvelle méthode efficace du traitement chirurgical des contractures cicatricielles après des brûlures. De plus, la transposition des plans et des lambeaux ne s'associait à aucune complication.

EXPOSÉ : Cette technique comporte de nombreux avantages. La plastie en K-M-N peut être utilisée en toute sécurité lorsque la tension cutanée traverse la ligne de contracture. Elle est supérieure aux autres lambeaux en raison de sa riche vascularité et de la mobilité des cicatrices superficielles. Elle peut être recommandée au chirurgien inexpérimenté parce qu'elle est facile à exécuter. De plus, c'est une intervention efficace des zones de péricontractures en raison de sa forme en V (elle peut prévenir une nouvelle contracture). La couleur et la texture qui en résultent sont plus acceptables sur le plan esthétique, sans compter que la correction de la contracture est similaire à celle des autres techniques. Il n'y a pas de surplus cutané aux extrémités. La plupart du temps, elle peut être exécutée sous anesthésie locale (pas chez les enfants) et la durée d'opération et d'hospitalisation est plus courte que dans le cas des autres techniques.

skin may require excision and recontraction of the resulting dog ear and/or Burow's triangle in the reconstruction of scar contractures. Although, Z-plasty is one of the most popular techniques used in the treatment of scar contractures, tip or distal flap necrosis may be seen in multiple Z-plasty procedures. Rhomboid flap may also be another treatment option – its design consists of the long axis parallel to the contracture band (3-5). There are many disadvantages and advantages of each technique for treating scar contractures; we tried to design a new modification of double-opposing Z- and V-plasty called 'K-M-N plasty'. The present paper discusses the K-M-N plasty procedure in detail.

METHODS

Between June 2004 and February 2009, the K-M-N plasty technique was performed on 18 (10 male and eight female) patients

Education and Research Hospital, Department of Plastic Reconstructive and Aesthetic Surgery, Erzurum, Turkey

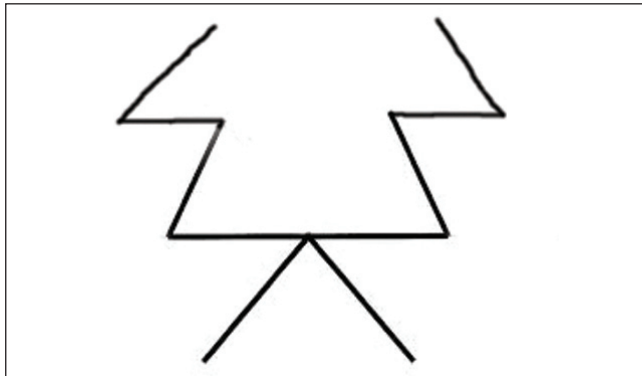
Correspondence: Dr Ilteris Murat Emsen, Atatürk Üniversitesi Tıp Fakültesi, 4. Blok, No:30, 25240 Erzurum, Turkey.

Telephone 90-442-2360722, fax 90-442-2321091, e-mail ilterisemsen@hotmail.com

TABLE 1
Patient characteristics

Age, years	Sex	Involved area	Etiology	Follow-up
9	M	Axillary region	Congenital band	4 years
21	M	Popliteal region	Scalding	13 months
65	F	Lateral canthal region	Old tension suturing	10 months
17	F	Antecubital region	Tandir burn	11 months
13	M	Axillary region and popliteal region	Fire burn	17 months
6	M	Popliteal region	Scalding	19 months
4	F	Neck	Tandir burn	21 months
9	F	Popliteal region and axillary region	Fire burn	20 months
9	M	Axillary region	Tandir burn	18 months
36	M	Web space	Scalding	12 months
20	M	Antecubital region and axillary region	Fire burn	14 months
19	F	Popliteal region	Scalding	23 months
15	M	Popliteal region and ankle	Scalding	20 months
19	F	Antecubital region and axillary region	Scalding	22 months
33	M	Web space	Tandir burn	9 months
16	M	Neck	Fire burn	19 months
7	F	Axillary region and popliteal region	Fire burn	24 months
5	F	Face	Tandir burn	10 months

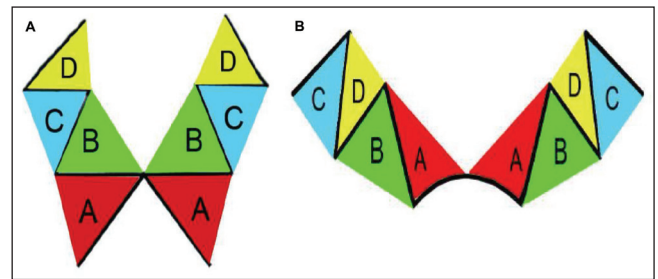
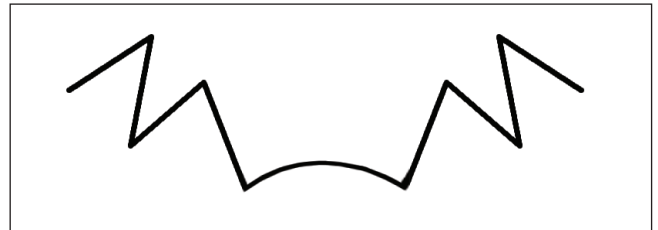
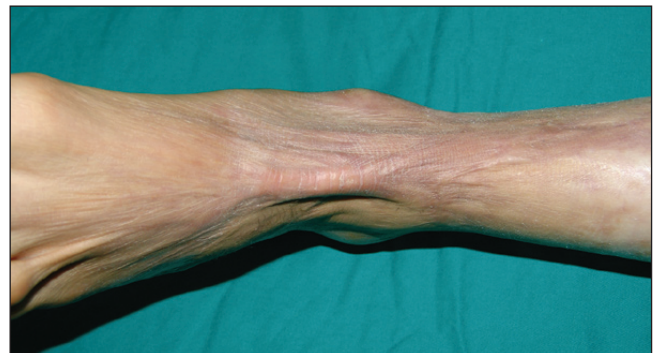F Female; M Male

**Figure 1)** Schematic drawing of the double-opposing Z- and V-plasty

with 20 postburn scar contractures (Table 1). The mean age of the patients was 17.9 years (range four to 65 years). The major etiological causes were scald burn in six patients, followed by tandir burn in five patients and fire burn in five patients. The burn localizations were in the axillary and/or popliteal region in 14 contractures, antecubital region in three contractures, web space in two contractures and neck region in two contractures. The lengths of the contractures ranged from 2 cm to 19 cm (mean length was 7.1 cm). All of the contractures were released using K-M-N plasty. Routine supportive care consisting of compressive garments and silicone gel application was given postoperatively.

Surgical technique

The operation can be performed under local (regional intravenous anesthesia or axillary block) or general anesthesia. (For children, general anesthesia is preferred; for adults and the elderly, local or regional anesthesia is preferred.) First, double-opposing Z-plasty is centred and marked along the long axis of the contracture to be

**Figure 2)** A (red in colour) and B (green in colour) triangles are the limbs of the double-opposing Z-plasty. C (blue in colour) and D (yellow in colour) triangles are the limbs of the V-plasty**Figure 3)** After flap elevation, new localizations of A, B, C and D flaps are seen**Figure 4)** Preoperative view of the left ankle of case 1

lengthened with 60° angles. Next, the V shape is added to the limbs of the marked or elevated Z-plasty with 60° angles (K-M-N flap drawing is shown in Figure 1). Due to the V shape or V-plasty, the tension or tension lines placed on the pericontracture area are broken. The incision depth of each K-M-N flap is continued to the deep fascia, and full lengthening is achieved. The K-M-N shape is obtained along the contracture line (transferred flaps are shown in Figures 1, 2 and 3).

Case 1

A 15-year-old boy with serious postburn contracture of the left ankle and lateral popliteal region due to a scald burn (Figure 4) sustained nine years previously was admitted. On reviewing his history, surgical reconstruction was not performed on his burn contracture; only dressings were used. He was operated on both his ankle and popliteal burn contractures. Double-opposing Z- and V-plasty flaps were drawn on his burned and contracted tissue (Figure 5), and full release was achieved. K-M-N flaps were sutured with 4/0 absorbable, and 5/0 and 6/0 nonabsorbable sutures; minimal ischemia was seen at follow-up (Figures 6, 7 and 8).

Case 2

A 65-year-old woman was admitted to the Education and Research Hospital (Erzurum, Turkey) due to a scar contracture

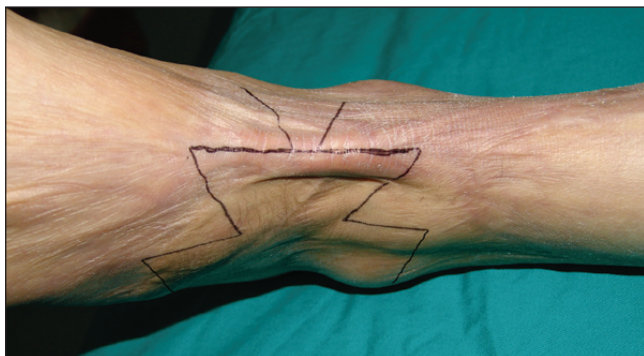

Figure 5) Marking of the double-opposing Z- and V-plasty flaps

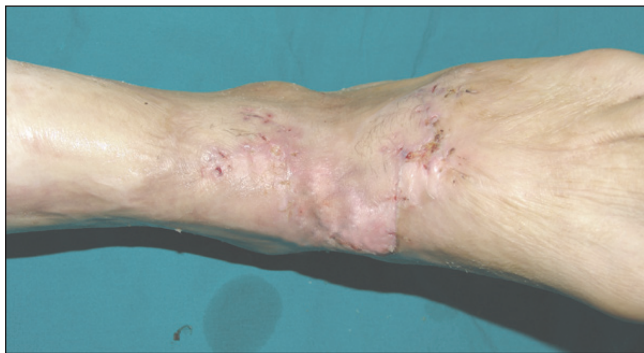


Figure 6) Late postoperative view: 20 months after surgery

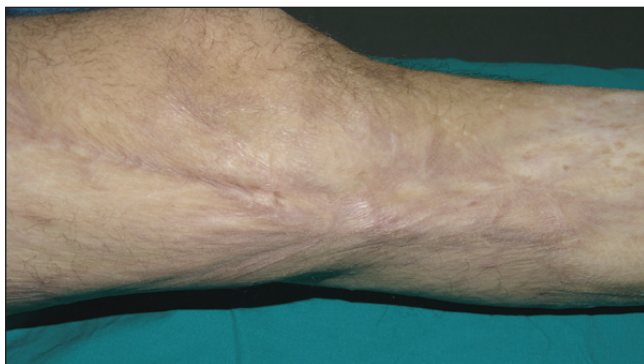


Figure 7) Preoperative view of the popliteal contracture of the same case

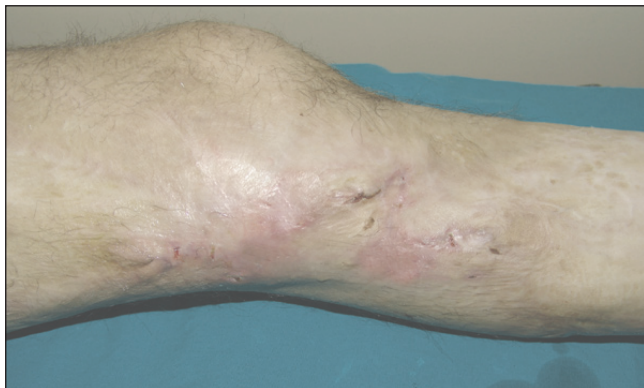


Figure 8) Late postoperative view of the popliteal region: 20 months after surgery

that had localized in the lateral canthal region of her left eye. Her medical history revealed that the injured site had been sutured under tension after a traffic accident in 2003 (Figure 9). She was operated on her lateral canthal contracture. Double-opposing

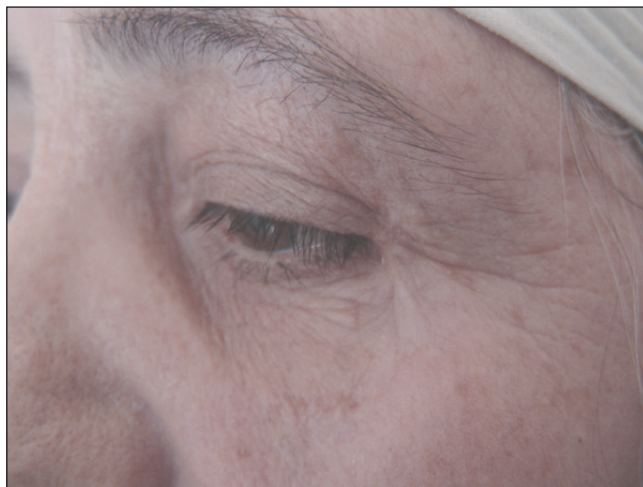


Figure 9) Preoperative view of a scar contracture in the lateral canthal region of the left eye of case 2

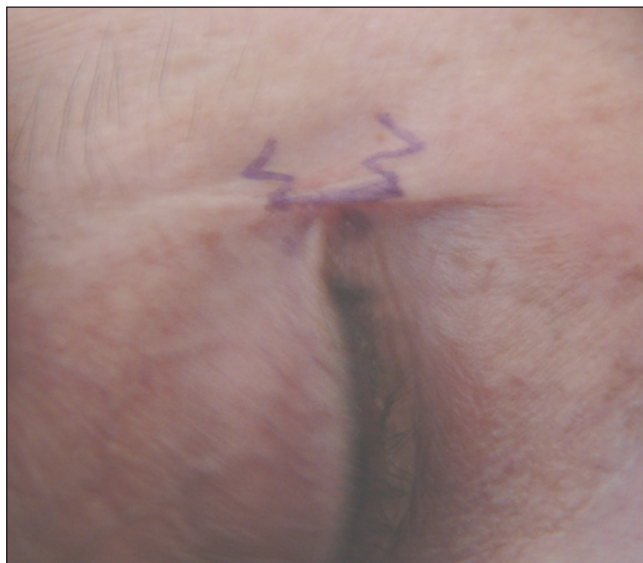

Figure 10) Design of the double-opposing Z- and V-plasty flaps

Z- and V-plasty flaps were drawn on her contracted site (Figure 10), and full release was achieved. K-M-N flaps were sutured with 4/0 absorbable, and 5/0 and 6/0 nonabsorbable sutures; ischemia was not seen at follow-up (Figure 11).

Case 3

A 36-year-old man was admitted to the Education and Research Hospital due to a postburn contracture that had localized in the left first web space. The contracture resulted from a scald burn that he sustained four years previously that was left to secondary healing with dressing (Figure 12). Two years later, web space contracture occurred, for which he was operated. Double-opposing Z- and V-plasty flaps were drawn on his contracted web space (Figure 13), and full release was achieved. K-M-N flaps were sutured with 4/0 absorbable, and 5/0 and 6/0 nonabsorbable sutures. No flap ischemia was seen at follow-up (Figures 14 and 15).

Case 4

A nine-year-old boy with a congenital axillary band and contracture localized in the left axillary area (Figure 16) was admitted. He

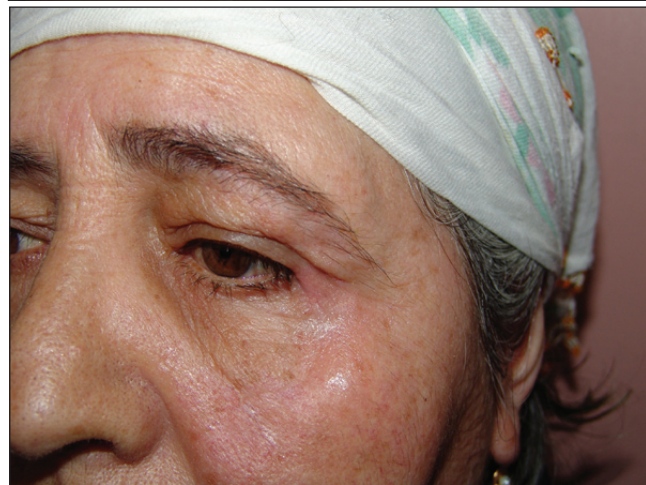
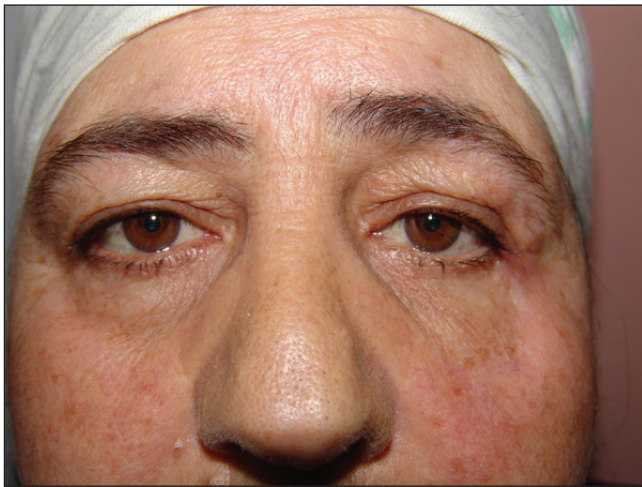
Figure 11) Early postoperative results: 10 months after surgery

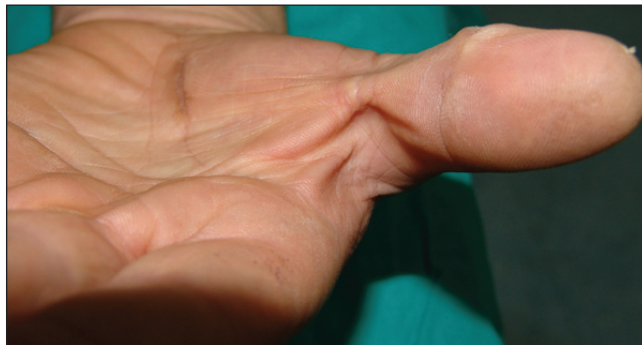

Figure 12) Preoperative view of a postburn contracture of the left first web space of case 3



Figure 13) Design and marking of the double-opposing Z- and V-plasty flaps

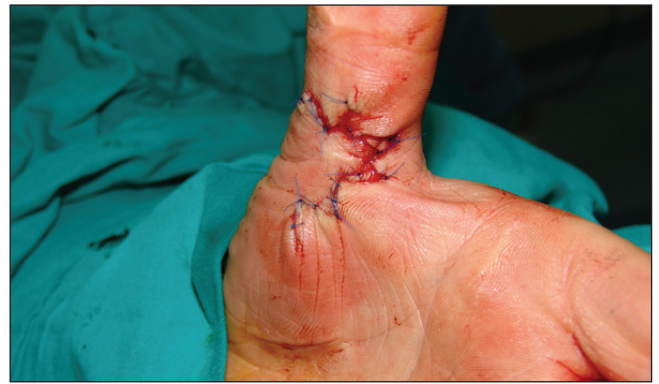

Figure 14) Sutured flaps are seen perioperatively

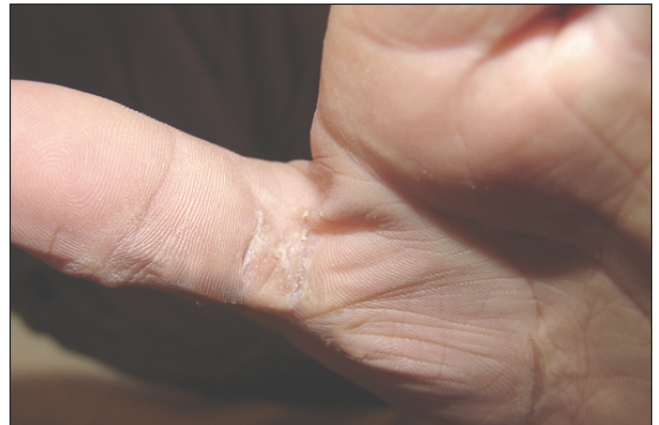

Figure 15) Early postoperative result with full lengthening: 12 months after surgery

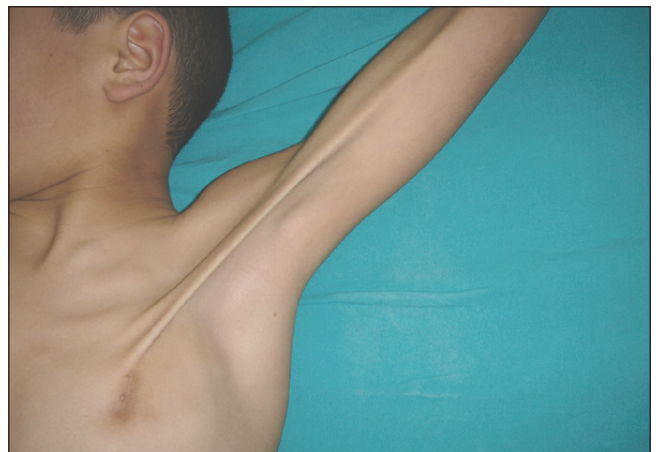

Figure 16) Preoperative view of the left axillary area of case 4

did not receive any treatment at the time of the injury. He was operated for his axillary webbing (due to severe abduction restriction in the arm). Double-opposing Z- and V-plasty flaps were drawn on his axillary webbing (Figure 17), and full release was achieved. K-M-N flaps were sutured with 4/0 absorbable, and 5/0 and 6/0 nonabsorbable sutures. No flap ischemia was seen at follow-up (Figure 18).

Case 5

A 17-year-old woman with an antecubital contracture that had localized in the left arm due to an old tandir burn was admitted (Figure 19). She had fallen into the tandir 10 years previously. At the time of the injury, only wound care was given by the

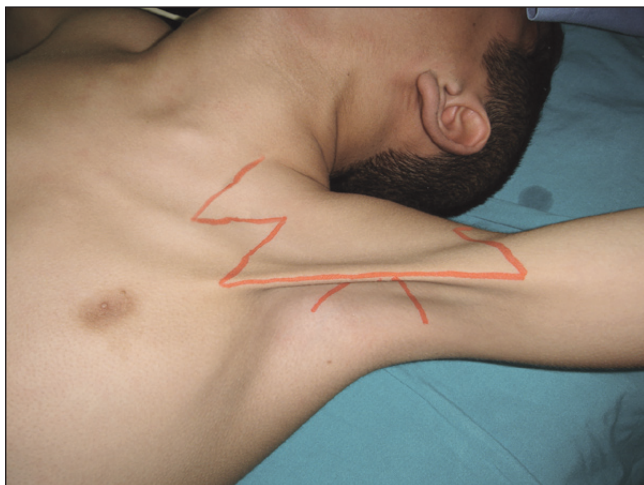


Figure 17) Design and marking of the double-opposing Z- and V-plasty flaps

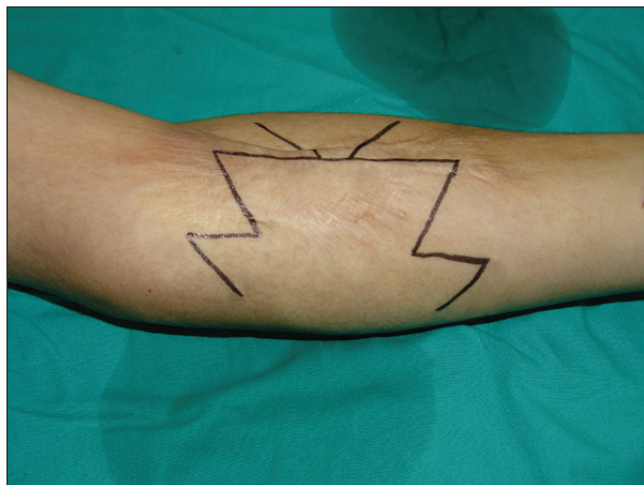

Figure 20) Preoperative marking of the double-opposing Z- and V-plasty flaps

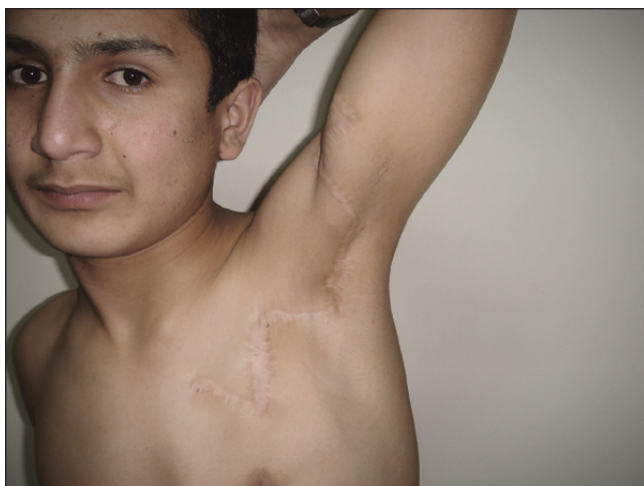

Figure 18) Late postoperative result: four years after surgery

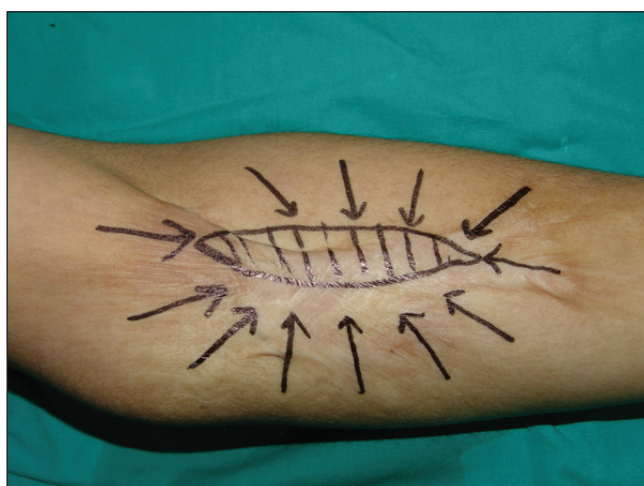


Figure 21) Pericontraction areas (arrows)

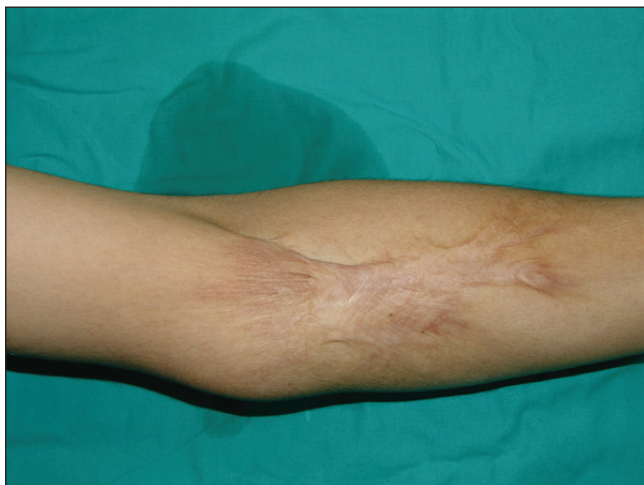


Figure 19) Preoperative view of the left arm of case 5

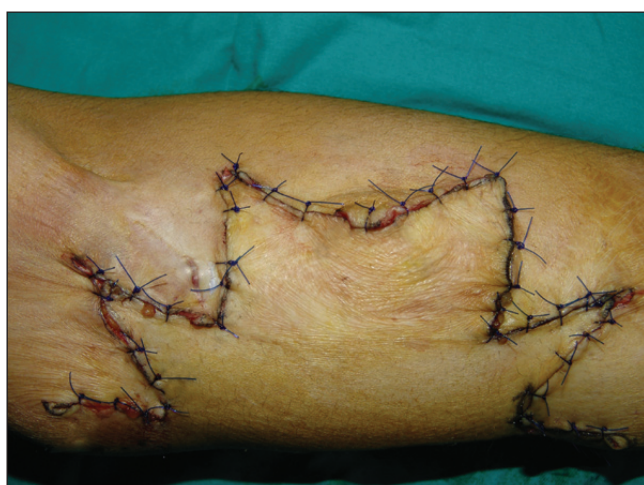

Figure 22) K-M-N flaps seen after full release of the contracture postoperatively

local village doctor. She was operated for her antecubital contracture. Double-opposing Z- and V-plasty flaps were drawn on her contracted area (Figure 20), and full release was achieved. K-M-N flaps were sutured with 4/0 absorbable, and 5/0 and 6/0 nonabsorbable sutures. No flap ischemia was seen at follow-up (Figures 21 and 22).

RESULTS

The mean follow-up time was 18.3 months (range nine to 40 months). No early complications such as hematoma, infection and wound dehiscence were seen in any of the patients. All flaps healed uneventfully without partial or total loss. Flap

ischemia or tip necrosis were not observed in the early post-operative period, and adequate lengthening and functional recovery were achieved in all cases. All patients regained function in their affected joints; patients had full range of motion, postoperatively. The donor area scars were acceptable in all cases. Patient satisfaction for K-M-N plasty scars in terms of both function and aesthetic outcomes was good. No recurrent contracture or ankylosis developed in any of the patients who had undergone the procedure.

DISCUSSION

The subcutaneous pedicle rhomboid flap technique was initially described by Uzunismail et al (6) in 1994, and this proposed technique was successfully used for the correction of digital and first web space contractures due to burn. In the following years, Askar (7) introduced a different rhomboid flap technique based on the subcutaneous pedicle; this flap was called double reverse V-Y-plasty. Next, Ertas et al (8) improved the subcutaneous rhomboid flap technique to be more effective in the reconstruction of different postburn scar contractures. This flap option (subcutaneous pedicle) has a reliable blood supply with a low risk of necrosis based on subcutaneous fat tissue. Preparing and performing the procedure is relatively easy and is superior to previous rhomboid flap techniques. However, all of these techniques have a major limitation and second flap options are needed to close the donor area – one of which is the rhomboid flap technique. This leads to linear scar formation and, perhaps, recurrence in later periods. In addition, one rhomboid flap design may not be sufficient to achieve adequate lengthening for patients with serious contracture. Multiple rhomboid flap options or additional flap options may be necessary for full recovery. Unfortunately, the use of multiple rhomboid flaps has a few disadvantages such as sequential and unnecessary scars. These disadvantages may increase the recurrence rate, and damage the fine and meticulous anatomical structures (depending on the location). Anatomical structures may have been destroyed, either fully or partially, due to previous burn injury; the original anatomical structures and their normal course cannot usually be found under the scars. The basic aim in the relaxation of the contracted areas or bands should not only be elongation or breakup of the contracted line, but also formation of both a broken scar line and periscar line in the released contracture site, thereby avoiding and stopping the recurrence of the contractures. According to some long-term follow-up results, releasing the contracted lines with rhomboid flaps can cause elongation, but the tendency of the contracture line to recur would be questionable. Scar lines cannot be broken with 45° to 30° angles as in the Z-plasty technique. In addition, one Z-plasty (classically a 60° angle) is satisfactory in short contracted areas. However, in long scars, a bigger Z-plasty is required. Big Z-plasties are not acceptable cosmetically and functionally. A major limitation in repeated or multiple Z-plasties is that the

upper Z-plasty can cause ischemic zones and flap necrosis under each Z-plasty because the upper located Z-plasty affects the lower Z-plasty's vascular territory. For this reason, many surgeons avoid repeated or multiple Z-plasties; in addition, areas with scars already have a low blood supply.

Furthermore, fascia or fasciocutaneous perforating vessels that underlie scars may have been destroyed in previous injury. In our cases, we tried to solve this problem using double-opposing Z- and V-plasties. The theoretical length gain for 60° angle Z-plasty is 75%. For example, a 1 cm scar would be 1.75 cm using a 60° angle Z-plasty. This lengthening is mostly obtained in 40% to 65% of cases (9,10). Increase in the elongation of the contracture line is achieved by adding new V-plasties on both sides of the M flap, and recurrence of the contracture is avoided by shaping the scar line in sharply broken incisions. We used 60° angle Z-plasties in our cases; we do not recommend using the other angles (such as 30°, 75° and 90°) due to tip necrosis in distal flaps. The most important rule in achieving relaxation of the contracted area with Z-plasty is elevating the triangle Z-plasty flaps entirely subfascially from the tip to the base of the flap. The perfusion of the triangle Z-plasty flaps can be preserved via subfascial plexus if performing no more than one Z-plasty. If performing multiple Z-plasties, these plexuses can be injured, resulting in uncontrollable flap necrosis. In our cases, no severe distal flap or tip necrosis was seen using double-opposing Z-plasty relaxations. Severe contracture lines crossing flexion folds can be released effectively using the double-opposing Z-plasty and V-plasty (K-M-N plasty) technique without distorting the specialized flexion areas. To avoid recurrent scar formation, broken scar lines are formed. Our technique is also very simple to design and apply; donor sites can be closed without skin grafting and tension suturing. The double-opposing Z- and V-plasty (K-M-N plasty) is also a fairly versatile technique to lengthen scar contractures, due to various causes such as burn and trauma, in any region of the body. We used this technique in both scarred and skin grafted areas in our series uneventfully.

CONCLUSION

Double-opposing Z- and V-plasty (K-M-N plasty) is a very useful technique to increase lengthening and to prevent recurrence in the treatment of serious postburn scar contractures. Thus, this method may be a good alternative to multiple Z-plasties and multiple rhomboid flaps and V-Y-Z in the treatment of long and wide postburn scar contractures.

NOTE: This study and the technique described was developed by the author and was performed on his patients at the Education and Research Hospital (Erzurum, Turkey). Patient consent for all published figures were obtained. This original article was accepted as an oral presentation at the XI Congress of Italian and American Plastic Surgeons, June 25 to June 28, 2008, in Bologna, Italy.

REFERENCES

1. Suzuki S, Um SC, Kim BM, Shin-ya K, Kawai K, Nishimura Y. Versatility of modified planimetric Z-plasties in the treatment of scar with contracture. *Br J Plast Surg* 1998;51:363-9.
2. Suzuki S, Matsuda K, Nishimura Y. Proposal for a new comprehensive classification of V-Y-plasty and its analogues:

The pros and cons of inverted versus ordinary Burow's triangle excision. *Plast Reconstr Surg* 1996;98:1016-22.

3. Borges AF Pitfalls in flap design. *Ann Plast Surg* 1982;9:201-10.
4. Hauben DJ. Ernst Blasius's contributions to plastic surgery. *Plast Reconstr Surg* 1984;74:561-70.

5. Suzuki S, Isshiki N, Ishikawa K, Ogawa Y. The use of subcutaneous pedicle flaps in the treatment of postburn scar contractures. *Plast Reconstr Surg* 1987;80:792-8.
 6. Uzunismail A, Kahveci R, Ozdemir A, Bozdogan N, Yuksel F. The rhomboid release: A new approach to the management of digital burn contractures. *Ann Mediterran Burns Club* 1994;8:94-7.
 7. Askar I. Double reverse V-Y-plasty in postburn scar contractures: A new modification of V-Y-plasty. *Burns* 2003;29:721-5.
 8. Ertas NM, Bozdogan N, Erbas O, Uscetin I, Kucukcelebi A, Celebioglu S. The use of subcutaneous pedicle rhomboid flap in the treatment of postburn scar contractures. *Ann Plast Surg* 2004;53:235-9.
 9. Furnas DW, Fischer GW. The Z-plasty: Biomechanics and mathematics. *Br J Plast Surg* 1971;24:144-60.
 10. Rohrich RJ, Zbar RI. A simplified algorithm for the use of Z-plasty. *Plast Reconstr Surg* 1999;103:1513-8.
-