



A variant accessory muscle of the gluteus maximus*

Published online February 10th, 2015 © <http://www.ijav.org>

Victor TAYLOR

Geoffrey D. GUTTMANN

Rustin E. REEVES †

Department of Integrative Physiology and Anatomy,
University of North Texas Health Science Center, Fort
Worth, Texas, USA.



† Rustin E. Reeves, PhD
Professor and Vice Chair for
Anatomy Education
Department of Integrative
Physiology and Anatomy
UNT Health Science Center
3500 Camp Bowie Blvd.
Fort Worth, TX 76107, USA.
☎ +1 (817) 735-2050
✉ rustin.reeves@unthsc.edu

Received February 20th, 2014; accepted May 20th, 2014

Abstract

Routine dissection of the gluteal region revealed an accessory muscle originating from the deep, inferior fibers of the gluteus maximus muscle. The described muscle was surrounded by a separate fascial sheath and contained fibers that converged into a tendon with origins from both the gluteus maximus muscle and the iliotibial tract (band). This tendon inserted on the proximal femur lateral to the intertrochanteric crest, slightly superior to the upper border of the gluteal tuberosity. Typically, the inferior fibers of the gluteus maximus muscle will insert into the gluteal tuberosity. This variant accessory muscle of the gluteus maximus seen with a separate muscle belly and tendinous insertion has not been previously described in the literature regarding the anatomy of the gluteal region.

© *Int J Anat Var (IJAV)*. 2015; 8: 10–11.

Key words [gluteus] [maximus] [variant] [tuberosity] [iliotibial]

Introduction

The gluteus maximus muscle is the largest and most powerful muscle in the gluteal region of the body. It is the most superficial of the three gluteal muscles, covering all of the others except for a small part of the gluteus medius muscle. The gluteus maximus slopes inferiolaterally at a 45° angle from the pelvis to the buttocks [1]. The approximate superior two-thirds of fibers of the gluteus maximus muscle insert laterally into the iliotibial tract (or iliotibial band) at its proximal end near the mid to inferior part of the tensor fasciae latae muscle. The remaining inferior fibers of the gluteus maximus insert into the gluteal tuberosity of the proximal femur. The iliotibial tract represents the lateral thickening of the fascia lata, forming a longitudinal band that passes over the greater trochanter and extends from the tubercle of the iliac crest to Gerdy's tubercle on the lateral side of the proximal tibia. The iliotibial tract serves as an attachment site for the gluteus maximus and tensor fascia latae muscles. With the gluteus maximus muscle, the iliotibial tract stabilizes the hip joint by preventing lateral displacement of the proximal end of the femur [2].

Case Report

As a part of a series of dissections with the intent to improve the anatomical understanding of Greater Trochanteric Pain

Syndrome (GTPS), a variant accessory muscle originating from the gluteus maximus muscle was observed in the right hip of a 79-year-old embalmed, female cadaver. Figure 1 shows the cadaver image of the right hip after initial reflection of the gluteus maximus muscle. This accessory muscle contained a distinct muscle body and tendon bound in a separate fascial sheath (Figure 1, arrowheads). Figure 2 represents a more detailed dissection of the reported hip clearly showing the variant muscle body arising from the inferior fibers of the gluteus maximus muscle (Figure 2, arrows). The variant muscle's tendon (Figure 2, asterisk) inserted on the proximal femur lateral to the intertrochanteric crest and superior to the upper boundary of the gluteal tuberosity. Additionally, we observed a small tendon that arose from the iliotibial tract and then inserted into the superior aspect of the variant muscle's tendon (Figure 2, arrowhead). The remaining deep fibers of the gluteus maximus muscle appeared to insert normally into the iliotibial tract near the tensor fasciae latae muscle and below on the gluteal tuberosity of the proximal femur (Figures 1 and 2, dashed lines).

Discussion

Greater trochanteric bursitis is a common diagnosed problem often associated with GTPS. This syndrome is usually the result of prolonged rubbing of the iliotibial tract on the greater trochanter, irritating and inflaming the bursa sac

* Presented in part at the 2013 annual meeting for the American Association of Anatomists in Boston, Massachusetts, USA (April 20–24, 2013).

surrounding the greater trochanter. Common symptoms to follow are swelling, tenderness, and pain that radiates in the lateral hip and often travels down the thigh [3]. The gluteus maximus muscle adjoins the iliotibial tract; hence lending support that it too may have implications in GTPS. In this anatomical study of GTPS, one of the specimens exhibited a variation in the deep, inferior fibers of the gluteus maximus muscle. The variant's tendon inserted into the proximal femur lateral to the intertrochanteric crest; a superior position to the deep, inferior fibers of the gluteus maximus muscle that normally insert into the gluteal tuberosity of the femur. This unusual insertion point for the variant tendon could have potentially caused GTPS-like symptoms in this individual.

The gluteus maximus muscle is a large muscle that has variable insertion sites for its numerous muscle fibers, with the superior part of the gluteus maximus inserting into the iliotibial tract [4]. In the hip dissections we observed (n=77), fibers of the gluteus maximus muscle merged with fibers from the iliotibial tract, primarily in a lateral and posterior position to the joint capsule. The deeper fibers of the inferior part of the gluteus maximus muscle attached to the gluteal tuberosity of the femur. The left hip from this cadaver was the only specimen observed with an accessory muscle originating from the main body of the gluteus maximus muscle. We have

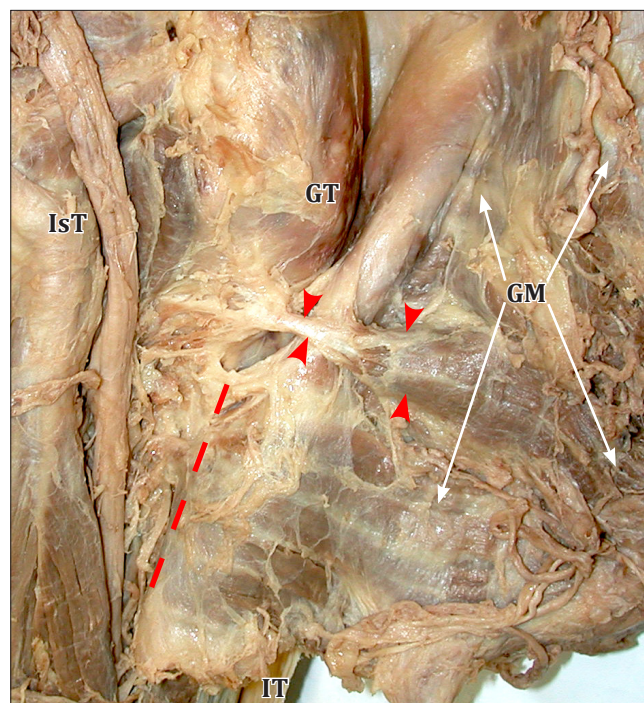


Figure 1. Posterior view of the right hip when the *gluteus maximus* muscle (**GM**) was first reflected. Note the separate fascial sheath surrounding the accessory muscle and tendon (**arrowheads**). Lower fibers from the gluteus maximus muscle insert below the accessory muscle's tendon at the *gluteal tuberosity* (**dashed lines**). (**IsT**: ischial tuberosity; **GT**: greater trochanter; **IT**: iliotibial tract)

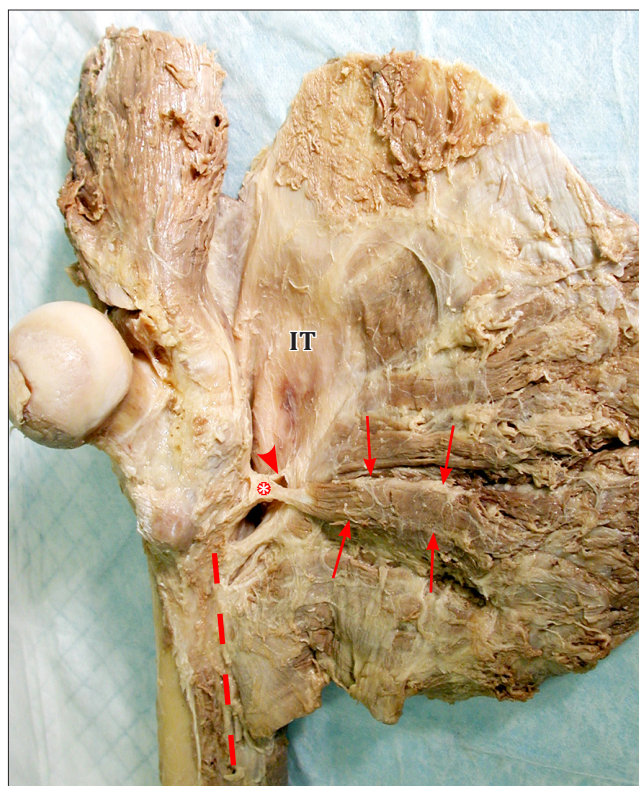


Figure 2. Posterior view of the detached right hip showing the gluteus maximus muscles and its variant accessory muscle reflected. This is the same hip as shown in Figure 1, but with a more detailed dissection. The *variant accessory muscle body* (**arrows**) can be clearly seen with its *tendon* (**asterisk**) inserting into the proximal femur, lateral to the intertrochanteric crest, and superior to the *gluteal tuberosity* (**dashed line**). Fibers from the *iliotibial tract* (**IT**) are shown inserting into the *accessory muscle's tendon* (**arrowhead**).

not found this variant described previously in the literature and believe it to be a unique anatomical variation.

Acknowledgement

We would like to thank Dr. Claire Kirchhoff for her support and assistance in the review and editing of this manuscript.

References

- [1] Moore KL, Dalley AF, Agur AMR. Clinically Oriented Anatomy. 6th Ed., Philadelphia, Lippincott Williams and Wilkins. 2010; 565–566.
- [2] Drake RL, Vogl AW, Mitchell AWM. Gray's Anatomy for Students. 2nd Ed., Philadelphia, Churchill Livingstone Elsevier. 2010; 545.
- [3] Williams BS, Cohen SP. Greater trochanteric pain syndrome: A review of anatomy, diagnosis, and treatment. *Anesth Analg*. 2009; 108: 1662–1670.
- [4] Vieira EL, Vieira EA, da Silva RT, Berlefin PA, Abdalla RJ, Cohen M. An anatomic study of iliotibial tract. *Arthroscopy*. 2007; 23: 269–274.