

Acupuncture and treatment of warts: Case study

Dr Sogand Zareisedehizadeh, MD, PhD, Acupuncturist¹

Dr Mehdy Ghaemina, MD, PhD, Acupuncturist¹

ABSTRACT

Statement of the Problem: Cutaneous wart is caused by Human Papilloma Virus (HPV). Therapeutic approach to this skin lesion is still a challenge because no certain therapy exists to achieve a complete remission in every patient. Moreover, most of the existing methods produce scars or post treatment hyper/hypopigmentation on the skin. Here, we present a simple method using acupuncture and moxibustion to treat the chronic wart lesions.

Methodology & Theoretical Orientation: Acupuncture with moxibustion was done on the cutaneous warts persisted for more than six months. Based on the fundamental theory of Chinese medicine, we strengthened the zhang organ-lung by simple needling of its front mu (LU1) and empowered the immune system balance with the needle stimulation of ST36 and CV4. Moreover, the needle was inserted using dragon on fire model with the wart lesion at the center. The lesion warmed up with a moxa stick without touching. The treatment was done twice a week and the improvement was monitored. The informed consent was taken from the patients before the treatment.

Findings: out of the 7 patients, 6 completely cured without remaining any post treatment scar or skin discoloration. The lesion in one out of 7 patients was shrunk but not completely removed (Figure1). The number of treatment sessions was between 4-10 sessions, mean 7. The latter case has had the treatment resistant wart lesion for about 9 years on the face, so, we are continuing the treatment.

Conclusion & Significance: This acupuncture and moxibustion method is effective, simple and safe for cutaneous warts and can be suggested as a therapeutic option. The mechanism of action may be rationalized based on the available studies showing the immunomodulatory effects of acupuncture. Compared to the acupuncture or western medicine methods presented in the literature for the treatment of this lesion, this method uses minimal numbers of needling and does not exert any post inflammatory reaction on the skin.

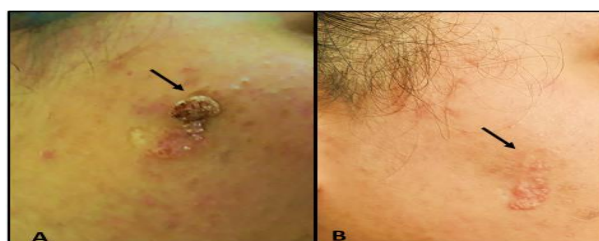


Figure 1: A) before and B) After the treatment

BIOGRAPHY

Dr. Sogand is a medical practitioner (MD) with PhD degree from National University of Singapore and an acupuncturist from Singapore College of Traditional Chinese Medicine. She has been involved in a wide range of medical research from in-vitro to in-vivo and the clinical studies with the main focus on the translational medical research and evaluation of herbal medicine for drug discovery purposes. One of her achievements is the result of her PhD project which has been kept confidentially by National University of Singapore for patent purposes.

Annual Congress on Traditional Medicine, Webinar | May 26-27, 2022

¹ Iranian Scientific Acupuncture Association, Iran

Citation: Dr. Sogand Zareisedehizadeh, Acupuncture and treatment of warts: Case Study, Annual Congress on Traditional Medicine, Webinar, May 26-27, 2022, 05