



Appendix duplication in association with persistent cloaca and type 2 pouch colon

Published online February 23rd, 2010 © <http://www.ijav.org>

Mehmet Emin BOLEKEN ^[1]

Erkan YILDIZ ^[2] ✉

Mete KAYA ^[1]

Mustafa DENIZ ^[2]

Departments Pediatric Surgery [1] and Anatomy [2], Harran University Faculty of Medicine, Sanliurfa, TURKEY.



✉ Erkan Yildiz, MD
Harran Üniversitesi
Tıp Fakültesi
Anatomi Anabilim Dalı
63100, Sanliurfa, TURKEY.
☎ +90 414 3148414
✉ eyildiz73@yahoo.com

Received November 18th, 2009; accepted February 18th, 2010

ABSTRACT

Duplication of the vermiform appendix is extremely rare, and it may be associated with gastrointestinal and genito-urinary anomalies in childhood. Presented herein is a case of association of appendix duplication, pouch colon, and persistent cloaca. Pathogenesis of this association is discussed. © IJAV. 2010; 3: 12–14.

Key words [appendix duplication] [persistent cloaca] [pouch colon]

Introduction

The incidence of appendix duplication has been estimated to range from 0.004 to 0.008% in the reported appendectomy series and usually found as an incidental finding during laparotomy for other intraabdominal reasons. In addition, accompanying intestinal, genito-urinary or vertebral malformations may be present when appendiceal duplications are detected in children.

The authors report a case of newborn with persistent cloaca and double appendices at laparotomy, and discuss the pathogenesis of appendix duplication.

Case Report

A full term, 7-day-old girl was transferred from local government hospital to the Department of Pediatric Surgery, Harran University Medical Faculty, with the provisional diagnosis of “imperforate anus”. There was no family history of malformations, consanguinity and no history of medication to the mother during pregnancy. Physical examination revealed evidences of persistent cloaca as an abdominal distention and a single perineal orifice with partially fused labia and absence of an anal orifice. Routine complete blood count and biochemical tests revealed no abnormalities except slight increase in white blood cells. The babygram showed no gross abnormality, and a plain abdominal radiograph displayed dilated loops of small bowel. Abdominopelvic ultrasonography showed a cystic mass occupying the upper pelvis and lower midline abdomen.

Exploratory laparotomy revealed intestinal malrotation with the terminal ileum on the left side. There was a mobile but normal cecum associated with two separated appendices (Figure 1). Both appendices located at opposing directions. Each of them had its own blood supply originated from appendicular arteries, both of which were given off by the ileocolic artery. The remainder of the large intestine was shortened, and continued with a pouch colon (10 cm in diameter) and communicated with the neck of bladder. Duplex uterus and vagina was part of the persistent cloaca. The appendices were removed in the usual manner. Then, diverting colostomy was performed. Histologically, both appendices were normal. The infant did well following surgery, and discharged on antibiotic therapy for the urinary infection on postoperative day 10. She is waiting for definitive surgery.

Discussion

Congenital anomalies of the appendix are rare; the two most commonly reported are congenital absence and appendiceal duplication. Appendix duplications are rarely symptomatic, most of them are diagnosed incidentally at laparotomy, and some of them can be detected on routine barium examination for other clinical reasons preoperatively [1]. Symptoms are usually the result of obstruction and inflammation. The clinical presentation can vary according to the location of the appendices [2]. Appendiceal duplications were first classified by Cave in 1936 by their anatomical locations [3]; in 1963, Wallbridge devised these anomalies based on reported cases [4].

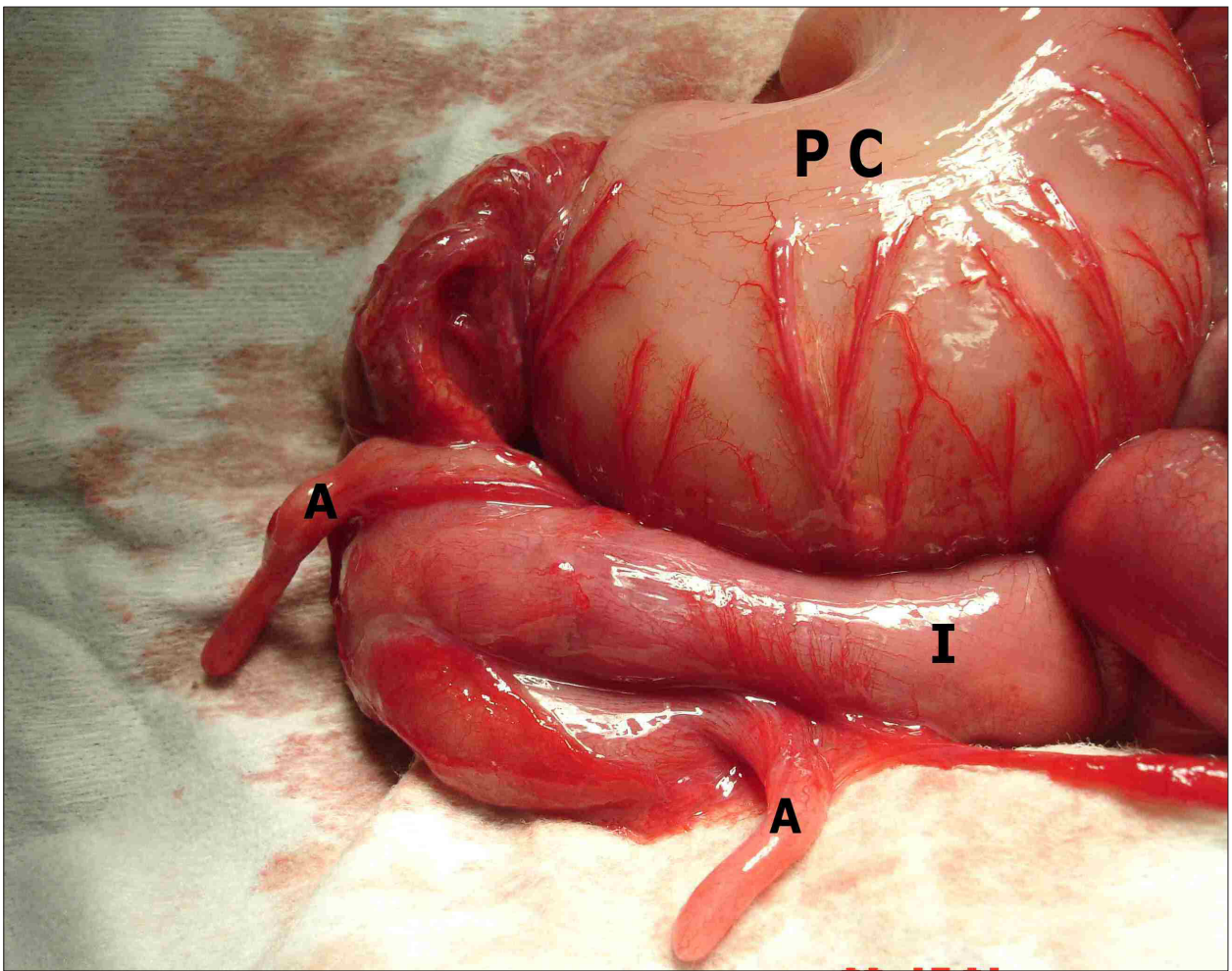


Figure 1. Photograph shows intraoperative appearance of the case. (A: duplex appendices; PC: pouch colon; I: ileum)

According to the Cave–Wallbridge classification, 3 types of duplicated appendix are described:

- i) Type A consists of various degrees of partial duplication on a normally localized appendix with a single cecum.
- ii) Type B consists of a single cecum with two completely separate appendices, divided into two further subgroups, Type B1 where two appendices are located symmetrically on either side of the ileocecal valve, resembling the normal arrangement in birds and termed “bird-like type”; and Type B2 which has a normally located appendix arising from the cecum at the usual site and a second separate rudimentary appendix located along the line of one of the taenia and as such termed “taenia-coli type”.
- iii) Type C consists of a duplicated cecum each with an appendix.

Our patient had an anomaly previously described and that represents an extension of the Cave–Wallbridge classification Type B2, i.e., *a form in which two separated appendices is attached to single cecum*.

Embryology of the normal appendix has been defined [5]. During the 5th fetal week it is the appendix which develops from a bud at the junction of the small and large bowel and undergoes rapid growth into a pouch. In the 6th

week there is a transient nubbin surmounting the pouch indicative of being involved in the rapid development of the pouch, which is very strategically placed near the apex of the highly significant midgut loop. It is only after the fifth fetal month that the proximal end of this pouch, which has appeared to be a very insignificant structure up until this stage, starts growing differentially to give rise to the true cecum which continues to develop into infancy.

Although normal embryogenesis of appendix is known, but the pathogenesis of its duplication is unclear. Furthermore, to explain the embryology of gastrointestinal duplications, following four theories put forward: The split notochord theory, failure of the normal regression of embryonic diverticula, the median septum formation, and partially twinning procedure [6]. Although the second theory may favor the pathogenesis, that there is failure of the normal regression of embryonic diverticula, none of them completely explains the embryology of appendix duplications. Nevertheless, Cave put forward two theories for the pathogenesis of duplex appendix: (a) supernumerary appendix due to persistence of a transient embryological structure; (b) appendical duplicity incidental to a more general affection of the primitive

midgut [3]. Cave's theories may explain this duplication, but they are not enough to explain all types.

The most of appendiceal duplications, especially types B1 and C duplications, are associated with other gastrointestinal and genitourinary abnormalities as in our case with congenital pouch colon and cloacal anomaly [7]. Although isolated appendix duplications have been reported, according to literature, interestingly, it has been described that appendiceal duplication is a component of the part of type 2 congenital pouch colon. In this type, the ileum opens into a short segment of cecum which then opens into the colonic pouch [8].

In both these conditions, there appears to be an arrest at an early stage in partitioning of the cloaca by the urorectal septum. With congenital pouch colon, it is likely that the primary abnormality is "defective organogenesis" or "primary dysplasia" of the distal-most segment of intestine close to the descending urorectal fold [9]. Yanar et al. also explained the possible relationship between the anorectal-genitourinary malformations and appendix duplications by the close anatomic association of the distal hindgut and the urogenital septum in the embryologic origin [7]. Also, one could speculate that they might result from abnormalities in the differentiation of the

hindgut to the urogenital and gastrointestinal processes. However, we could find a few reported associations in the published literature between appendix duplication, anorectal malformations. Rizalar et al. reported a case of duplication of appendix vermiformis in a baby with myeloschisis and anal atresia associated with segmental dilatation of the colon [10]. Kothari et al. reported a case of appendix duplication associated with imperforated anus [2]. Chadha et al. have described the association of appendix duplication with pouch colon and anorectal malformations in 6 patients of their series [9]. But no detailed informations were given to explain the pathogenesis.

In conclusion, exact pathogenesis is not known, but some point in the management of appendiceal duplication has been clarified [11]: (i) especially type B duplications, where the second appendix base may lie at any point along the colon, present the greatest risk of missing the second appendix; (ii) appendiceal duplication may also present as a constricting lesion of the ascending colon and mimic a colonic adenocarcinoma; (iii) some cases of duplicated appendix are associated with intestinal, genitourinary, or vertebral malformations, and this needs to be considered after diagnosis.

References

- [1] Peddu P, Sidhu PS. Appearance of a type B duplex appendix on barium enema. *Br J Radiol.* 2004; 77: 248–249.
- [2] Kothari AA, Yagnik KR, Hathila VP. Duplication of vermiform appendix. *J Postgrad Med.* 2004; 50: 285–286.
- [3] Cave AJ. Appendix vermiformis duplex. *J Anat.* 1936; 70: 283–292.
- [4] Wallbridge PH. Double appendix. *Br J Surg.* 1962; 50: 346–347.
- [5] Glover JW. The human vermiform appendix – a general surgeon's reflections. *EN Tech J.* 1988; 3: 31–38.
- [6] Jimenez SG, Oliver MR, Stokes KB, Morreau PN, Chow CW. Case report: Colonic duplication: a rare cause of obstruction. *J Gastroenterol Hepatol.* 1999; 14: 889–892.
- [7] Yanar H, Ertekin C, Unal ES, Taviloglu K, Guloglu R, Mete O. The case of acute appendicitis and appendiceal duplication. *Acta Chir Belg.* 2004; 104: 736–738.
- [8] Puri A, Chadha R, Choudhury SR, Garg A. Congenital pouch colon: follow-up and functional results after definitive surgery. *J Pediatr Surg.* 2006; 41: 1413–1419.
- [9] Chadha R, Bagga D, Mahajan JK, Gupta S. Congenital pouch colon revisited. *J Pediatr Surg.* 1998; 33: 1510–1515.
- [10] Rizalar R, Sarac A, Gork AS, Somuncu S, Bernay F, Gurses N. Duplication of appendix with segmental dilatation of the colon, myeloschisis and anal atresia. *Eur J Pediatr Surg.* 1996; 6: 112–113.
- [11] Griffiths EA, Jagadeesan J, Fasih T, Mercer-Jones M. Bilid vermiform appendix: a case report. *Curr Surg.* 2006; 63: 176–178.