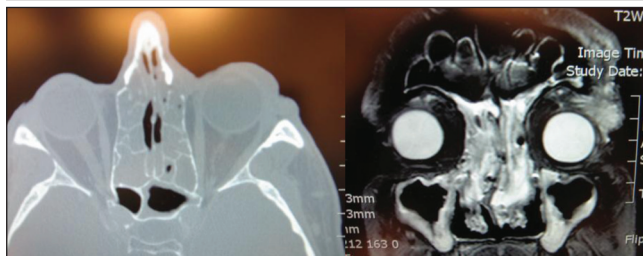
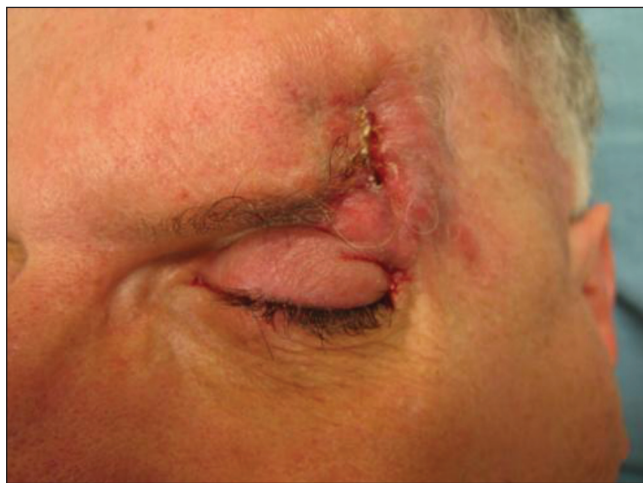

ORAL EXAM

Case 1

Basal cell carcinoma

A 54-year-old man with a history of basal cell carcinoma who underwent an excision one year previously, presents with a recurrent lesion



Objective 1: The candidate demonstrates ability to conduct an appropriate physical examination of a cutaneous neoplasm

Question 1:

What specific findings are important on physical examination

Eye exam

Lid function

Mobility

Nerve function

Lymph nodes

Objective 2: The candidate can order and interpret appropriate investigations

Question 2:

On examination the eye function is normal with the exception of ptosis and inability to elevate the lid. The lesion is firm and fixed, and approximately 2 cm × 3cm.

What investigations, would you order?

CT/MRI

You order a CT scan and MRI which are completed. Please discuss your relevant pathological findings from these two films.

GIVE CANDIDATE ADDITIONAL PHOTOS

Involvement of Lacrimal gland

Lateral rectus

Extends along lateral orbital wall

No intracranial/intraconal involvement

Around lateral orbital rim

Objective 3: The candidate can develop a collaborative management plan.

Question 3:

What is your management plan for this patient?

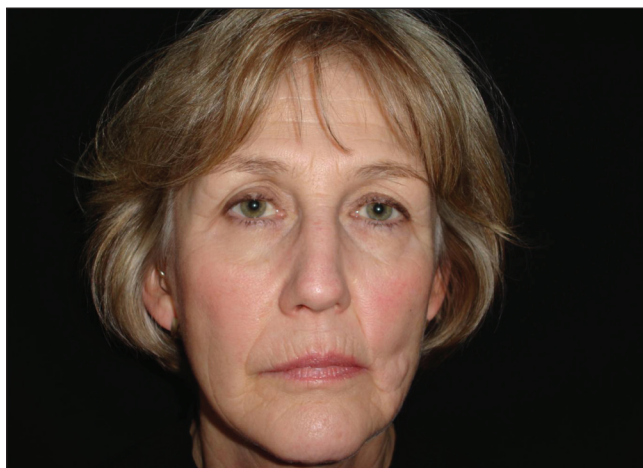Consultations – Ophthalmology/neurosurgery

Pathology for frozen section excision

Case 2

Use of botox in aesthetics

An otherwise healthy 55-year-old women who is concerned about her aging appearance



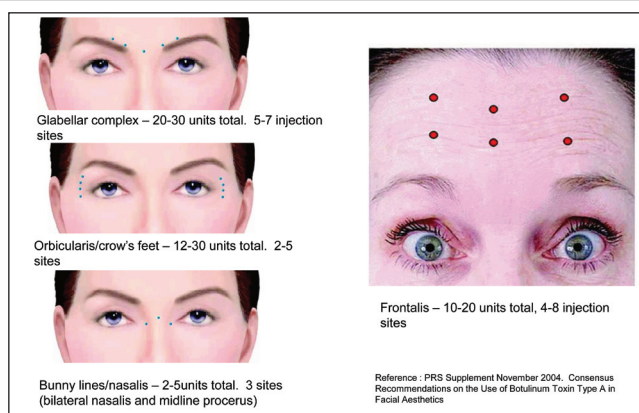
Objective 1: The candidate can describe the use and complications of botox.

Question 1:

This woman is requesting botox to address the dynamic wrinkles on her face.

Which wrinkles in her upper face would you consider addressing with botox?

Glabellar/Crows feet/Transverse nasal lines/Transverse forehead lines



Which muscles produce them?

Glabellar Lines – Orbicularis/depressor supercilli/procerus/corrugator

Crows feet – Orbicularis

Bunny lines – Nasalis/Procerus

Transverse forehead lines – Frontalis

You choose to proceed with botox injections for her upper face dynamic wrinkles.

GIVE CANDIDATE TRANSPARENCY TO MARK LOCATIONS

For the glabellar lines, where would you inject? What dose would you use?

Crow's feet? What dose?

Bunny lines/nasal root lines? What dose?

Transverse forehead lines? What dose?

Key Answers: See photograph above

Question 2:

List two complications specific to box injection

Allergy/ptosis/no effect