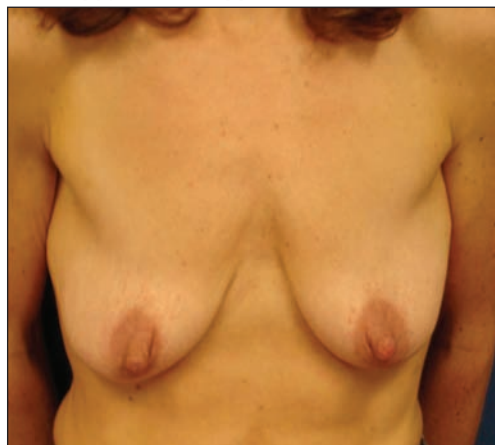

## ORAL EXAM

### Case 1

#### Mastopexy augmentation

A 54-year-old G4P4 woman comes to see you because she is unhappy with the appearance of her breasts



Objective 1: The candidate can describe the evaluation of a patient presenting with post-partum atrophy.

Question 1:

Could you please describe the features of importance on physical examination

Skin quality – thin skin with poor elasticity  
Significant ptosis – Grade 2 or 3  
Relatively similar size and shape of both sides  
Poor soft tissue coverage (especially in the superior pole of the breast)

Objective 2: The candidate can describe an operative approach.

Question 2:

This patient would like to restore the position of her breasts and to increase their volume – could you describe the surgical procedures that you would offer to her?

Mastopexy/augmentation

Staged procedure involving mastopexy and then augmentation

Question 3:

The patient would like to have a single-stage procedure and has agreed to a mastopexy augmentation. Please describe your operative technique?

Submuscular versus subglandular augmentation (depending on assessment of soft tissue coverage in the upper pole)

Consideration of type of mastopexy – periareolar, vertical scar, wise pattern

Placement of incisions

Question 4:

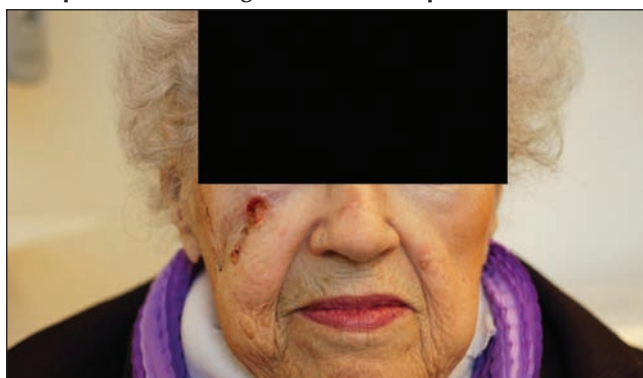
You decide to perform a vertical scar mastopexy augmentation. Please draw your markings.

Answer to this requires that the candidate can perform markings for a vertical augmentation mastopexy

### Case 2

#### Basal cell cancer

A 79-year-old woman presents with a lesion that has been present on her right cheek for the past 10 months



Objective 1: The candidate demonstrates ability to formulate a differential diagnosis.

Question 1:

What is your differential diagnosis for this lesion?

BCC

SCC

Melanoma

Other malignant neoplasm

Benign neoplasm

Inflammatory

Objective 2: The candidate can order and interpret appropriate investigations.

Question 2:

What investigations would you order?

Incisional biopsy

Objective 3: The candidate can develop a management plan.

Question 3:

Incisional biopsy demonstrates a sclerosing BCC. What is your surgical approach to the resection of this lesion

Frozen section margin control

Excision with a skin graft or dressing pending definitive pathology for margins

Question 4:

You decide to perform the excision with frozen section margin control. At the conclusion of the resection you are left with the following defect (See additional photo 1). What are your surgical options for reconstruction?

Split thickness skin graft

Full thickness skin graft

Cervicofacial flap

Free flap

Question 5:

You decide to perform a cervicofacial flap. Please draw your markings. The candidate can draw the surgical markings appropriate for a cervicofacial flap

#### Additional photo 1

