



Double spinal dural sheath: a cadaveric case report

Published online March 4th, 2010 © http://www.ijav.org

Peter LOUGHENBURY †
Sharan WADHWANI
Roger SOAMES

School of Biomedical Sciences, University of Leeds, Leeds LS2 9JT, UNITED KINGDOM.



† Peter Loughenbury BSc (Hons) MRCS
School of Biomedical Sciences
University of Leeds
Leeds
LS2 9JT, UNITED KINGDOM.
☎ +44 113 243 1751
✉ prloughenbury@hotmail.com

Received August 27th, 2009; accepted December 3rd, 2009

ABSTRACT

A previously unreported variation in the anatomy of the spinal dural sheath was observed during routine cadaveric dissection, consisting of a duplication of the dural layer, with layers adherent throughout their length. The double dural sheath completely enveloped the spinal cord and nerve roots, and extended from C2 to L5: both layers were of similar thickness to a single dural sheath. Duplication of the dura mater in the form of two complete dural sheaths has not been previously observed and/or reported in a cadaveric study. However, areas of localised duplication of the ventral aspect of the dural sheath have been observed during intra-operative dissection, particularly in association with idiopathic herniation of the spinal cord. Complete duplication of the spinal dura mater is of clinical interest in spinal surgery, particularly in relation to idiopathic spinal cord herniation. © IJAV. 2010; 3: 41–43.

Key words [dural sheath] [duplication] [anatomical variation]

Introduction

The spinal dura mater is a dense inelastic membrane which forms a loose sheath around the spinal cord. It is attached to the circumference of the foramen magnum, and the posterior surface of the bodies of the second and third cervical vertebrae. At the level of the second sacral vertebra it invests the filum terminale and descends to the posterior aspect of the coccyx, where it blends with the periosteum. The embryological origin of the dura is unclear, arising either separately to the pia and arachnoid layers (dura from the *pachymeninx*, arachnoid and pia from the *leptomeninges*) or a common origin [1]. There are several reported anatomical variants of the dural sheath, including areas of localised duplication on its ventral aspect [2,3]. However, these have only been observed during intra-operative dissection and were then associated with idiopathic herniation of the spinal cord.

The present case study describes a complete duplication of the spinal dura mater in an otherwise 'healthy' cadaver, a previously undocumented variation. It is of clinical interest in spinal surgery, particularly in relation to idiopathic spinal cord herniation.

Case Report

The variant was noted during routine dissection of an embalmed 79-year-old male cadaver. Skin and subcutaneous tissue had been carefully dissected to expose the vertebral column from the dorsal aspect.

The extrinsic ligamentous support of the column was divided, and access to the vertebral canal was achieved via a translaminar approach. Removal of the vertebral arches and connecting ligaments between C2 and L5 exposed the spinal cord and meninges adjacent to the deep aspect of the posterior longitudinal ligament (PLL), vertebral bodies and intervertebral discs. The dura mater and spinal cord were sectioned transversely at T7, and a midline incision made along the length of the posterior dura mater from C2 to L5 exposing the spinal cord, which was reflected, leaving the anterior dura mater in situ against the posterior aspect of the vertebral bodies. Following the longitudinal incision it was apparent that more than one layer of dura mater was present (Figure 1).

Anteriorly the dura mater was firmly attached to the PLL and spinal nerve sheaths, particularly in the lower thoracic and lumbar regions. Blunt dissection revealed that the dural sheath consisted of two layers adherent throughout their length, with both layers completely enveloping the spinal cord and nerve roots, and merging caudally with the filum terminale. Each layer was of similar thickness, however the external layer tended to be thicker anteriorly and less consistent in thickness posteriorly particularly above the level of T10.

From the most cranial point observed (C2) to the level of the T10/T11 intervertebral disc the outer layer of the dura mater was strongly adherent to the deep layer of the PLL in the midline: below this level the attachment was

* Presented at The Joint meeting of the British and American Associations of Clinical Anatomists, New York, USA (July 2005).

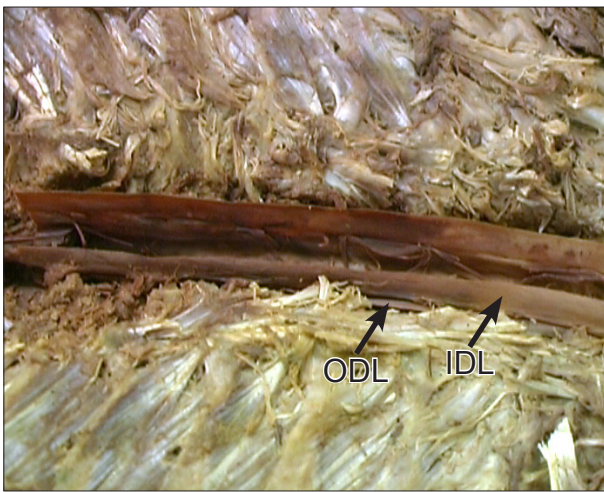


Figure 1. Dorsal view showing dissection of the thoracic spine (T7 to T12). The duplicated spinal dural sheath is shown, with the spinal cord removed. Cranial vertebral levels are towards the left. (ODL: outer dural layer; IDL: inner dural layer)

largely by loose fibrous tissue. The deep and superficial layers of the PLL, as well as the peridural membrane anterior to the PLL, showed the usual morphology [4]. Fewer anterior dural (Hofmann's) ligaments were present than observed in other cadaveric preparations [5]. The dural layers were not studied histologically, nevertheless their gross appearance and consistency was similar. A diagrammatic representation of the double dural sheath is shown in Figure 2.

Discussion

Complete duplication of the spinal dura mater is rare and, to our knowledge, has not been previously reported in a cadaveric study. However, areas of duplicated spinal dura mater have been noted in clinical case reports of spinal cord herniation and arachnoid cysts. The present case study describes a complete duplication of the spinal dura mater in an otherwise 'healthy' cadaver.

Previous reports [2,3] of duplication of the ventral aspect of the spinal dura, which were observed during intra-operative dissection, linked it with idiopathic herniation of the spinal cord. Oe et al. [3] presented a case of idiopathic herniation of the spinal cord associated with ventral duplication of the dura and a dorsal subarachnoid cyst, which was present at the level of dural duplication. The additional dural layer was resected, however the patient showed no clinical improvement. Nakazawa et al. [2] reported two patients with Brown-Séquard syndrome, which both clinically and radiologically (CT myelography and MRI) was consistent with a ventral arachnoid cyst. Intra-operative dissection demonstrated idiopathic spinal cord herniation accompanied by a localised duplication of the ventral dura mater, which in one patient extended from C6 to T5. The constricting area of dura mater resected in both patients, after which they improved eventually returning to work.

Idiopathic herniation of the spinal cord tends to occur ventrally through the dura mater due to the normal

kyphosis of the thoracic spine. In all reported cases there appears to be a weakened area of dura secondary to a pathological process (e.g. erosion of the vertebral body) or due to a congenital abnormality: the weakness frequently being accompanied by a dorsal intradural arachnoid cyst [6,7]. Where duplication of dura mater is responsible for the weakness, it seems most likely that the duplication is a congenital abnormality. Nakazawa et al. [2] suggested that the mechanism for herniation observed in their patients was a physiological kyphosis of the thoracic spine coexisting with a congenitally duplicated dura mater. A weakness/defect in the inner dural layer could enable cerebrospinal fluid to become insinuated between the two layers creating a cavity. The ventral side of the spinal cord could then make contact with this defect during flexion and/or extension of the vertebral column, giving rise to the symptoms seen.

A complete duplication of the spinal dura mater, as reported here, is most probably a congenital abnormality, however given the thickness of each of the two layers it is unlikely that this would result in a weakness of the dura mater. There was no evidence of cavitation between the two dural layers or of thinning and localised expansion of the external layer, suggesting that the individual layers were not significantly weaker. Furthermore, the layers were of similar thickness to a 'normal' single dural layer: previous reports of duplication have not commented on the thickness of individual layers.

As there is no consensus as to the embryological origin of the dura mater it is difficult to suggest how anatomical variants may occur. The spinal dura has traditionally been considered to arise from the *pachymeninx*, with the arachnoid and pia arising from the *leptomeninges*. However, some sources [1] have suggested a common origin for all three meningeal layers. It is possible that the presence of two substantial dural layers, as reported here, represent a dual origin from both *pachymeninx* and *leptomeninges*. Furthermore, the external dural layer in the present study was closely adherent to the PLL in the cervical and thoracic regions.

Although there are a limited number of reports of duplicated spinal dura mater all are of ventral duplication. However, it must be assumed that duplication can also

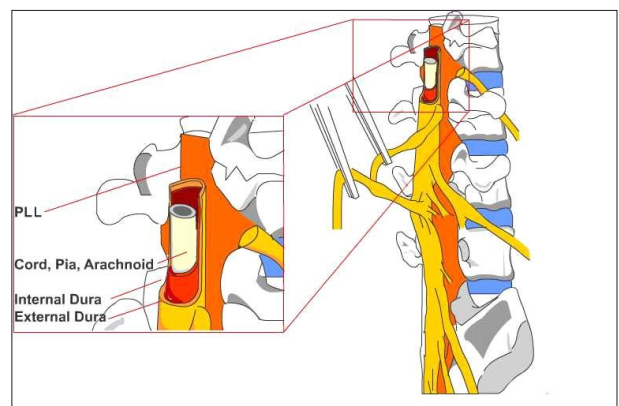


Figure 2. Diagrammatic representation of the anatomical variation.

occur dorsally without clinical consequence, with duplication being more common than previously thought. In the present study the associated lack of Hofmann's ligaments suggests a structural role for the duplicated dura.

It appears that there is a spectrum of occurrence, ranging from small areas of localised duplication to a complete duplication of the entire spinal dura mater as reported here, with its clinical significance being dependant on the site of, rather than the extent of, duplication.

References

- [1] Collins P. Embryology and Development. In: Williams, PL, Bannister, LH, Berry MM, Collins P, Dyson M, Dussek JE, Ferguson MWJ, eds. *Gray's Anatomy*. 38th Ed., London, Churchill-Livingstone. 1995; 257.
- [2] Nakazawa H, Toyama Y, Satomi K, Fujimura Y, Hirabayashi K. Idiopathic spinal cord herniation: report of two cases and review of the literature. *Spine*. 1993; 18: 2138–2141.
- [3] De T, Hoshino Y, Kurokawa T. A case of idiopathic herniation of the spinal cord associated with duplicated dura mater and with an arachnoid cyst. *Nippon Seikeigeka Gakkai Zasshi (Journal of the Japanese Orthopaedic Association)*. 1990; 64: 43–48.
- [4] Loughenbury P, Wadhvani S, Soames RW. The posterior longitudinal ligament and peridural (epidural) membrane. *Clin Anat*. 2006; 19: 487–492.
- [5] Wadhvani S, Loughenbury P, Soames RW. The anterior dural (Hofmann) ligaments. *Spine*. 2004; 29: 823–827.
- [6] Nagakawa H, Kamimura M, Uchiyama S, Takahara K, Itsubo T, Miyasaka T. Idiopathic spinal cord herniation associated with a large erosive bone defects: a case report and review of the literature. *J Spinal Disord Tech*. 2003; 16: 289–305.
- [7] Stoutos P, Arbit E, Tsairis P, Gargan R. Spontaneous thoracic spinal cord herniation: A case report. *Spine*. 1996; 21: 1710–1713.