

Elongated styloid process – report of three cases

Published online February 23rd, 2010 © <http://www.ijav.org>

Kiran V. PADEYAPPANAVAR⁽¹⁾ /
 Ameer Khusru KAZI⁽²⁾
 Amarappa NAGALEEKAR⁽¹⁾
 Deepali KULKARNI⁽¹⁾
 Umesh KULKARNI⁽¹⁾
 Vilas HUKKERI⁽¹⁾

Department of Anatomy, Belgaum Institute of Medical Sciences, Belgaum⁽¹⁾ and
 Department of Anatomy, Al-Ameen Medical College, Bijapur⁽²⁾, INDIA



+ Kiran V. Padeyappanavar
 Assistant Professor
 Department of Anatomy
 Belgaum Institute of Medical Sciences
 Civil Hospital Campus
 Belgaum, 590001, INDIA.
 ☎ +91 988 6237512
 ✉ dr.kiranvp@gmail.com

Received July 30th, 2009; accepted January 22nd, 2010

ABSTRACT

During routine osteology discussion classes for under graduate students, it was observed in 3 of the skulls that their styloid processes were elongated on both the sides approximately measuring more than 5 cm in length. © IJAV. 2010; 3: 30–32.

RETRACTED ARTICLE

Please check the notice of retraction at:

Tunali S. Notice of retraction. International Journal of Anatomical Variations. 2010; 3: 117.

Key words [styloid process] [skull] [Eagle's syndrome] [stylohyoid ligament] [dysphagia]

Introduction

Elongated styloid process or calcified stylohyoid ligament can cause recurrent throat pain along with foreign body sensation, dysphagia or facial pain. Additional symptoms may include neck or throat pain with radiation to ipsilateral ear.

In adults the styloid process is approximately 2.5 cm in length and its tip is located between the external and internal carotid arteries, just lateral to the tonsillar fossa [1].

Case Report

During the routine course of osteology discussion with undergraduate students it was observed in three dried human skulls approximately of 40 to 50 years old, their styloid processes were elongated (Figure 1).

The length of the styloid processes were measured with the help of a measuring tape (Table 1).

Table 1. The lengths of the styloid processes in three cases.

Skull	Length in cm	
	Left	Right
A	5.0	4.5
B	5.5	4.0
C	5.0	5.2

Discussion

The styloid process is a slender, elongated, cylindrical bony projection that lies anteromedial to the mastoid process. It normally varies in length from 2 cm to 3 cm, and a styloid process longer than 3 cm is found in 4 to 7 % of the population. The styloid process has attachments to three muscles and two ligaments [2]. The stylopharyngeus, stylohyoid and styloglossus muscles originate here. The facial nerve emerges from the stylomastoid foramen posteriorly. The stylohyoid ligament extends from the styloid process to the lesser horn of the hyoid bone.

The styloid process, stylohyoid ligament and lesser horn of the hyoid bone are derived from Reichert's cartilage, which arises from the second branchial arch. The cause of elongation of the styloid process has not been fully elucidated. Several theories have been proposed.

1) Congenital elongation of the process due to persistence of a cartilaginous anlage in the stylohyale. 2) Calcification of the stylohyoid ligament giving the appearance of an elongated styloid process. 3) Growth of osseous tissue at the insertion of the stylohyoid ligament [3].

The third theory is based on histological evidence of metaplastic changes to the subperiosteal cells in the vicinity of the ligaments insertion. Regardless of the pathophysiology of elongation, the result is a rigid, abnormally long structure that can cause pain or discomfort by one or several mechanisms.

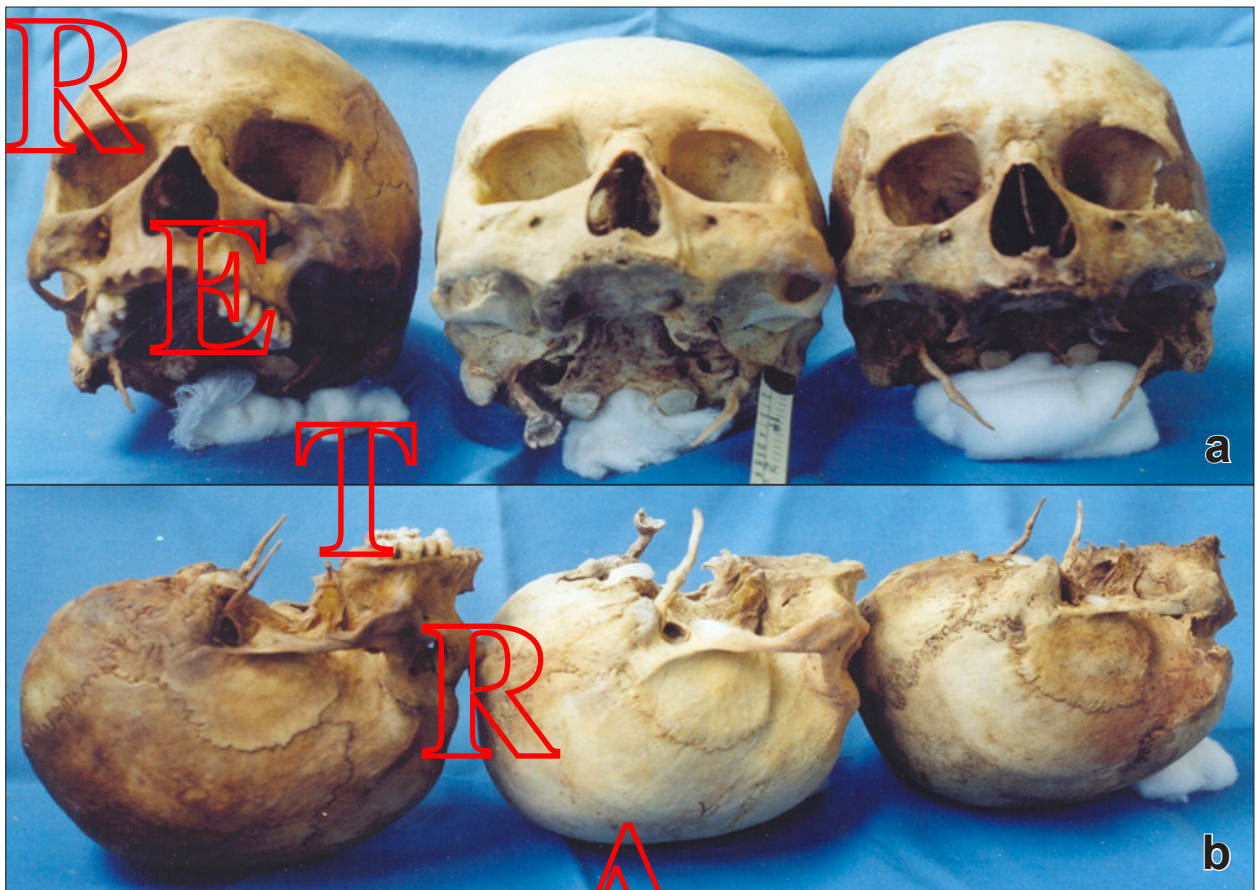


Figure 1. Photographs of skulls showing elongated styloid processes. a) Anterior view. b) Lateral view.

Elongated styloid process or calcified stylohyoid ligament can cause recurrent throat pain along with foreign body sensation, dysphagia or facial pain. Elongated styloid process is a diagnosis that should be considered in the evaluation of recurrent neck, throat or facial pain and dysphagia.

Additional symptoms may include neck or throat pain with radiation to the ipsilateral ear. In adults the styloid process is approximately 2 to 3 cms in length and its tip is located between external and internal carotid arteries just lateral to the tonsillar fossa. It may develop inflammatory changes or impinge on the adjacent arteries, on sensory nerve endings leading to the symptoms described. Diagnosis can usually be made on physical examination by digital palpation of the styloid process in the tonsillar fossa, which exacerbates the pain. In addition relief of symptoms with injection of an anesthetic solution in to the tonsillar fossa is highly suggestive of this diagnosis. Radiographic work up should include antero-posterior and lateral skull films. The treatment of Eagle's syndrome is primarily surgical. The styloid process can be shortened through an intraoral or external approach [4].

The first report of the anatomic pathology was by Marchetti of Padua who described the ossification of the stylohyoid ligament.

The pain syndrome was recognized by Weinlecher surgically excise the styloid process to treat a symptomatic patient.

Other isolated cases were reported until Eagle described the syndrome in 1937. Eagle divided the syndrome into two categories. He described the classic syndrome as persistent pain in the pharynx, aggravated by swallowing with the pain frequently referred to the ear on the side of the elongated styloid process. He also noted increased salivation, hesitancy, difficulty in swallowing, gagging and a foreign body sensation [5,6].

Fritz reported that only 11 of 43 patients with the syndrome in his series has had tonsillectomy. Both Eagle and Fritz reported that their patients were completely relieved of symptoms by the intraoral shortening of the styloid process [7].

Harma noted that bilateral elongation occurred in 50 % of the patients but only half of them had bilateral symptoms [8].

Steinmann reported the syndrome in 30 patients, 26 of whom did not have an elongated styloid process [9].

Keur et al. assessed 1135 edentulous patients clinically and radiographically to determine the relationship between the elongated styloid process and four symptoms frequently encountered in patients with Eagle's syndrome [10].

Conclusion

Eagle's syndrome though it is a rare entity it is largely under diagnosed. A thorough clinical and radiological examination will reveal impending insult. Proper

diagnosis can definitely be of immense help to rationalize the line of management and the ultimate clinical outcome.

References

- [1] Hollinshead WH. *Anatomy for Surgeons. The Head and Neck*, 3rd ed., Vol. 1. Philadelphia, JB Lippincott Co. 1982; 365.
- [2] Steinmann EP. A new light on the pathogenesis of the styloid syndrome. *Arch Otolaryngol.* 1970; 91: 171–174.
- [3] Balasubramanian S. The ossification of the stylohyoid ligament and its relation to facial pain. *Br Dent J.* 1964; 116: 108–111.
- [4] Strauss M, Zohar Y, Laurian N. Elongated styloid process syndrome: intraoral versus external approach for styloid surgery. *Laryngoscope.* 1985; 95: 976–978.
- [5] Eagle WW. Elongated styloid process. *Arch Otolaryngol.* 1937; 25: 584–587.
- [6] Eagle WW. Elongated styloid process: symptoms and treatment. *AMA Arch Otolaryngol.* 1958; 64: 172–176.
- [7] Fritz M. Elongated styloid process: cause of obscure throat symptoms. *Arch Otolaryngol.* 1940; 91: 911–918.
- [8] Harma R. Stylalgia. *Acta Otolaryngol (Stockh).* 1967; 224: 149–155.
- [9] Steinmann EP. Styloid syndrome in absence of an elongated process. *Acta Otolaryngol.* 1968; 66: 347–356.
- [10] Keur JJ, Campbell JP, McCarthy JF, Ralph WJ. The clinical significance of the elongated styloid process. *Oral Surg Oral Med Oral Pathol.* 1986; 61: 399–404.

R

A

C

T

E

D