

Ultrasound imaging compared to manual palpation to determine lumbar anatomy for neuraxial anaesthesia

Alisa Wilson

Wilson A. Ultrasound imaging compared to manual palpation to determine lumbar anatomy for neuraxial anaesthesia. *J Nurs Res Prac.* 2023; 7(4):1-5.

ABSTRACT

Background: Neuraxial anesthesia represents the final set of procedures used by nurse anesthetists that are performed in a blind fashion. However, the use of ultrasound guidance is changing the way these procedures have been performed.

Purpose: The purpose of this study is to explore differences in manual palpation versus ultrasound imaging in identifying vertebral anatomy and the duration of time needed for Student Registered Nurse Anesthetists (SRNAs).

Methods: Manual palpation and ultrasound imaging were compared on two Standardized Patients (SP's) in the sitting and

lateral positions to determine the accuracy and time needed to identify the L3-L4 intervertebral space by SRNAs.

Results: Results of a chi-square analysis indicated that SRNAs identified the L3-L4 intervertebral space more accurately utilizing ultrasound imaging compared to manual palpation in the sitting (SP 1: $p=0.0087$ / SP 2: $p=0.0228$) and lateral positions (SP 1: $p=0.0003$ / SP 2: $p=0.0196$). A Wilcoxon signed rank analysis indicated that SRNAs took significantly less time determining L3-L4 interspace with manual palpation compared to ultrasound imaging in both the sitting and lateral positions.

Conclusion: Although the duration of the procedure was significantly longer with ultrasound imaging, the accuracy of vertebral identification was much more precise.

Key Words: Epidural; Neuraxial anesthesia; Ultrasound; Neuraxial; Nursing; Spinal

INTRODUCTION

Determining lumbar anatomy for neuraxial anesthesia: Ultrasound imaging compared to manual palpation

Neuraxial anesthesia, comprised of spinal or epidural placement, represents the final set of procedures that are executed in a blind fashion [1-3]. These procedures are commonly performed with the anesthesia provider using a manual palpation technique. Anesthesia providers palpate the patient's superior iliac crests, transfer to a posterior midline position, and attempt to place the needle within the intervertebral space, most commonly attempting the procedure in the L3-L4 interspace. This procedure is done in either the sitting or lateral decubitus position. For obese patients or those diagnosed with spinal abnormalities, performing neuraxial anesthesia can present a significant challenge. However, as technology has advanced, the use of ultrasound imaging is changing the way these procedures have been performed [4].

The need for neuraxial ultrasound capability is increasing and has become a recommended adjunct by the American Association of Nurse Anesthetists. Utilizing pre-procedure ultrasound imaging provides the ability to see the anatomical landmarks and best entry point for the procedure. Ultrasound imaging causes no additional risk to the patient. However, there is potential to increase the amount of time for the duration of the procedure [4]. Furthermore, manual palpation techniques have been shown to be less accurate when determining the vertebral interspace where the procedure is being performed. When ultrasound imaging is performed correctly, the anesthesia provider can accurately determine the vertebral interspace and level of entry for the procedure [5].

Anesthesia providers currently utilize ultrasound imaging for procedures such as peripheral nerve blockade and central venous catheter insertion. However, despite the current literature, ultrasound imaging is less commonly performed when placing neuraxial anesthesia. Knowledge of use of ultrasound imaging may enhance the

Faculty of Health Science, School of Nursing, United State.

Correspondence: Alisa Wilson, Faculty of Health Science, School of Nursing, United State, e-mail Wilson_a@edu

Received: 3 Dec, 2023, Manuscript No. *puljnrp-24-6868*, Editor Assigned: 4 Dec, 2023, PreQC No. *puljnrp-24-6868* (PQ), Reviewed: 17 Dec, 2023, QC No. *puljnrp-24-6868* (Q), Revised: 19 Dec, 2023, Manuscript No. *puljnrp-24-6868* (R), Published: 28 Dec, 2023, DOI-10.37532/ 10.37532/ *Puljnrp.23.7(4).1-5*.



This open-access article is distributed under the terms of the Creative Commons Attribution Non-Commercial License (CC BY-NC) (<http://creativecommons.org/licenses/by-nc/4.0/>), which permits reuse, distribution and reproduction of the article, provided that the original work is properly cited and the reuse is restricted to noncommercial purposes. For commercial reuse, contact reprints@pulsus.com

provider's ability, patient safety, accuracy, and procedural success rates with minimal to no consequences. Currently, a large majority of the research has been conducted on those with palpable body surface landmarks. However, ultrasound imaging may be most beneficial on those presenting with impalpable body surface landmarks or previous spinal procedures.

Anatomical identification

Perlas, reported that anesthesia providers who utilized pre-procedure ultrasound imaging had a significant increase in identifying the appropriate intervertebral level compared to those performing manual palpation. Gosh determined that the vertebral interspace identified by manual palpation was typically one to three times higher than the actual vertebral interspace. Li reviewed anatomical accuracy in obese patients in the lateral position requesting neuraxial anesthesia. When using manual palpation, providers were challenged when determining a point of insertion and path for needle direction. The ultrasound group demonstrated three times less skin puncture attempts than the manual palpation group, once again signifying the importance of ultrasound imaging to determine the vertebral interspace and point of entry for neuraxial anesthesia.

The objectives were to:

When searching for articles that used a variety of participants including those with impalpable spinous processes, obesity, increased age, or previous spinal abnormalities, pre-procedure ultrasound imaging was found to be superior to manual palpation techniques. Creaney found a significant reduction in the number of attempts and needle redirects when using ultrasound imaging ($p=0.03$). Jain et al. (2019) further discussed how eight patients experienced complications in the palpation group versus zero patients in the ultrasound group ($p=0.003$). Researchers consistently reported an increase in the number of first attempt success rates, less needle advancements or redirects, and higher patient satisfaction rates when utilizing ultrasound imaging over manual palpation [6-7]

Duration of the Procedure

Throughout the literature review, duration of the procedure was addressed in multiple articles. However, the results have varied regarding the length of the procedure with manual palpation compared to pre-procedure ultrasound imaging. Arzola, found that the duration of the procedure was extended in the ultrasound group compared to the palpation group ($p= 0.06$). Creaney reported that the entire duration was longer, but the procedure itself was shorter in the ultrasound group. The time used for marking the insertion point was significantly longer in the ultrasound group ($p<0.001$), yet time from needle insertion to procedure completion was shorter in the ultrasound group. Li, found no difference in the duration of time to determine needle insertion points between both groups. The total procedure duration and needle-in-skin time was shorter in the ultrasound group ($p<0.001$). Tawfik found a 30-second reduction in time when utilizing pre-procedure ultrasound imaging compared to manual palpation.

As ultrasound imaging is gaining popularity and becoming a necessary tool for anesthesia providers, there is a need to train and educate SRNAs on both manual palpation and neuraxial ultrasound imaging. Therefore, a quality improvement project was completed within a

nurse anesthesia program's simulation laboratory. The purpose of the project was to assess for differences in palpation versus ultrasound imaging in identifying vertebral anatomy and the duration of time needed for a novice learner on two SP's. Ultimately, this would ensure the SRNAs have the skills and ability to utilize additional adjuncts and tools in the clinical setting when needed [6].

MATERIALS AND METHODS

Institutional review board approval to conduct this quality improvement project in a Nurse Anesthesia program was obtained from the academic home of the program. The program enrolled 68 SRNAs, 34 first year and 34-second year participants. The Principal Investigator (PI) invited all SRNAs currently enrolled in the nurse anesthesia program to participate via email. There was no credit given for participation and all participants were there voluntarily during a university break within the program. Participants had undergone a minimum of didactic neuraxial anesthesia education to varying levels of clinical training. SRNAs within the nurse anesthesia program were instructed to identify the L3- L4 intervertebral space using both manual palpation and ultrasound imaging on two SP's in the simulation laboratory. The total time needed and accuracy of identifying the intervertebral space with manual palpation and ultrasound imaging was recorded and compared on the two SP's in both the sitting and lateral positions.

Participants

Sixty-eight SRNAs enrolled in the nurse anesthesia program were offered the opportunity to participate in the proposed project. In a statistical power analysis, a sample of 33 participants was needed to demonstrate a statistical significance for the primary outcome of correctly identifying vertebral anatomy between the two methods. Overall, a total of 38 SRNAs volunteered and completed the study. In addition, two SP's were utilized for the project. Neither of these SP's have any medical knowledge nor affiliation with the university. Standardized patient 1 was a female, 34 years old, 5'6" in height, 170 pounds with a Body Mass Index (BMI) of 27.4. Standardized patient 2 was a male, 57 years old, 5'10" in height, 228 pounds, with a BMI of 32.7. The simulation coordinator and the PI were involved in the data collection as the experts in neuraxial ultrasound imaging and present at all times to determine anatomical landmarks. All participants used a Sonosite Edge ultrasound machine with a curved array probe to complete the ultrasound assessment.

Intervention and Data Collection

Participants were given a scheduled day and time to meet in the simulation laboratory. The participants had the option to withdraw from the study at any time. Once arrived, participants read and signed an informed consent and were given verbal instructions. Participants were assigned an identification number, which correlated to the informed consent. Only the PI, co-investigator, and the individual participants were aware of the individual identification numbers. The PI recorded the ability of the SRNAs to accurately identify the L3-L4 intervertebral space and the time utilized with both manual palpation and ultrasound imaging on two SP's in both the sitting and lateral positions.

Participants began with SP 1. They were given verbal instructions again and reminded that they would be timed. Once they were ready, the

instructor began the timer and participants used manual palpation to mark the L3-L4 intervertebral space while the SP was in the lateral position. The timer was stopped once the mark was placed. The SRNAs repeated the process with the SP in the lateral position using ultrasound imaging. The SP then moved to the sitting position, where the participant began with manual palpation again followed by ultrasound imaging. All four methods were individually timed. The marks were then removed prior to the arrival of the next participant. When the participants completed the process with SP 1, they moved to station 2 with the second SP (SP 2) and repeated the process. The primary outcome of accurately identifying the L3-L4 intervertebral space was recorded as correct or incorrect. If incorrect, the actual space identified was recorded. Time taken to identify the space was recorded as minutes and seconds. All outcomes of this study were noninvasive with no added risk to study participants or standardized patients. Two members of the team were directly involved in the project. These members include the simulation coordinator and the PI, both of whom are experts in neuraxial ultrasound. Study participants were not told whether their estimates were correct, or the timeframe used.

RESULTS

Data Analysis

The primary objective of this project was to determine the best practice method for performing neuraxial anesthesia. When determining accuracy in identifying the vertebral interspace it was predicted that ultrasound imaging would be more accurate than manual palpation. To analyze the quantitative data for the primary outcome being correct or incorrect identification of the L3-L4 intervertebral space, a chi-square test was used to determine a p value. Duration of time was then measured as a secondary outcome for each SP in both the sitting and lateral positions. A p value was determined using a non-parametric Wilcoxon signed rank test. In addition, the mean and median values were analyzed and compared.

A statistically significant difference was demonstrated between the percent correct versus incorrect in both the sitting and lateral positions with ultrasound imaging versus manual palpation on SP 1. While utilizing ultrasound imaging, SRNAs identified the L3-L4 intervertebral space more accurately than when using manual palpation in the sitting position ($p=0.0087$) and lateral position ($p=0.0003$). For SP 2, there was also a significant difference between the accuracy in identifying the L3-L4 intervertebral space when using ultrasound imaging compared to manual palpation in the sitting position ($p=0.0228$) and the lateral position ($p=0.0196$).

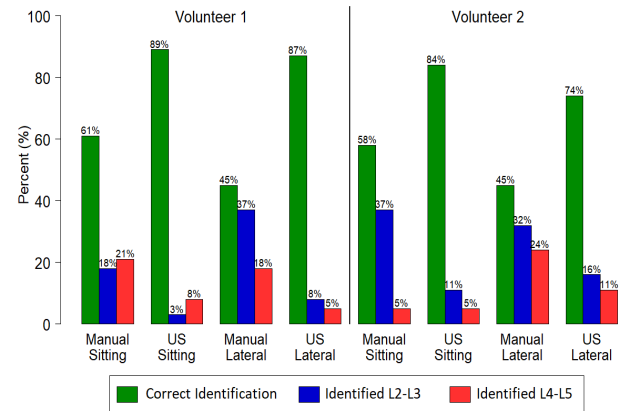


Figure 1) Accuracy of vertebral identification across two standardized patients with manual palpation and ultrasound imaging in the lateral and sitting positions

For those that identified the L3-L4 intervertebral space inaccurately, the actual vertebral space identified was recorded. On SP 1, in the lateral position with manual palpation, 37% of the inaccurate identifications were in the L2-L3 intervertebral space with 18% identifying L4-L5 (Figure 1). However, when that same SP moved to the sitting position, 18% identified L2-L3 with 21% identifying L4-L5 using manual palpation. Although there was an increase in the accuracy with ultrasound imaging, 8% of the SRNAs identified L2-L3 with ultrasound in the lateral position and 5% identified L4-L5. When in the sitting position 3% identified L2-L3 with ultrasound and 8% identified L4-L5.

For the second SP, 32% of inaccurate identifications were at the L2-L3 intervertebral space when utilizing manual palpation in the lateral position and 37% in the sitting position. However, 24% of the inaccurate markings were in the L4-L5 intervertebral space in the lateral position with only 5% in the sitting position with manual palpation. When using ultrasound imaging 16% marked L2-L3 in the lateral position and 11% in the sitting position. The L4- L5 space was identified 4 times (11%) in the lateral position with ultrasound imaging compared to 2 times (5%) in the sitting position (see Table 1).

Time

In SP 1 and SP 2, there was a statistically significant difference with manual palpation using less time than ultrasound imaging in the sitting and lateral positions ($p<0.0001$). For SP 1, the mean time used for manual palpation in the sitting position was 14.63 seconds and 28.80 seconds using ultrasound imaging in the sitting position. In the lateral position, the mean time for manual palpation was 14.79 seconds and 28.40 seconds with ultrasound imaging. The duration for SP 2 in the sitting position was 16.37 seconds for manual palpation and 54.72 seconds for ultrasound imaging. The mean time in the lateral position was 15.47 seconds for manual palpation and 59.75 seconds for ultrasound imaging (Figure 2).

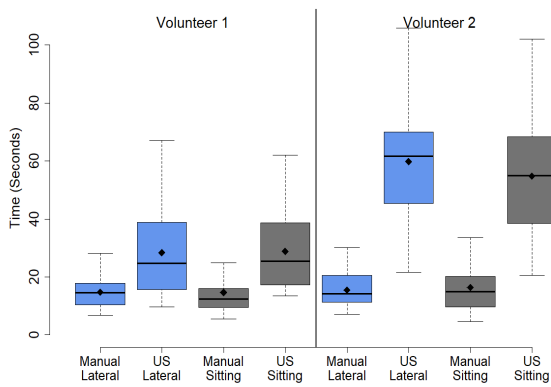


Figure 2) Boxplot showing the mean and median duration of time in the two SPs with manual palpation and ultrasound imaging in the sitting and lateral position

DISCUSSION

Neuraxial anesthesia is one of the last procedures performed in a blind fashion. Clinical Practice Guidelines are now recommending the use of neuraxial ultrasound imaging prior to the placement of neuraxial anesthesia on any patients that show signs of potential difficulty. Therefore, providers must understand how to utilize this technology and understand the benefits for the patient and provider.

In the lateral position, 87% of SRNAs identified L3-L4 using ultrasound imaging versus 45% with manual palpation for SP 1. In SP 2, 74% correctly identified L3-L4 intervertebral space using ultrasound imaging versus 45% with manual palpation. In the sitting position 89% correctly identified the vertebral anatomy using ultrasound imaging for SP 1 versus 58% with manual palpation. In SP 2, 84% were correct with ultrasound imaging in the sitting position versus 61% using manual palpation. One reason for the difference in time and accuracy from SP 1 to SP 2 could be the difference in patient demographics. SP 2 had a higher BMI than SP 1 and needed more time for SRNAs to visualize landmarks for ultrasound imaging. In addition, SP 2 was considered to have more impalpable body surface landmarks compared to SP 1. Although the secondary outcome of time was significantly longer when using ultrasound imaging, the correct identification of vertebral anatomy was shown to be more accurate with ultrasound imaging.

By utilizing ultrasound imaging prior to neuraxial anesthesia placement, there are increased first attempt success rates, patient satisfaction, and less needle punctures. The current literature supports the use of ultrasound imaging. However, there is a practice gap between the literature and the clinical setting as providers are lacking knowledge on the use of this technology. The results of this study may provide SRNAs with the ability to utilize a clinical facility's equipment to perform ultrasound imaging prior to neuraxial placement, which could decrease the current practice gap between literature and clinical practice. In addition, the education given to the SRNAs on neuraxial ultrasound can be transferred to current anesthesia providers during a one-hour in-service at a clinical facility. Replication of the project could be performed at any clinical facility or university that has an ultrasound machine with a curved array probe.

First attempt success rates have shown to be increased when anesthesia

providers utilize pre-procedural ultrasound imaging in clinical practice [8-10]. By increasing the success rates, there is a decrease in the likelihood of complications associated with the procedure and higher patient satisfaction scores [11]. Throughout this project, there was an increase in accurately identifying vertebral anatomy with ultrasound imaging compared to manual palpation in each SP. Therefore, having the knowledge and skills to perform neuraxial ultrasound imaging will enhance the provider's ability and decrease the current practice gap between literature and the clinical setting.

REFERENCES

1. Li M, Ni X, Xu Z et al. Ultrasound-assisted technology versus the conventional landmark location method in spinal anesthesia for cesarean delivery in obese parturients: a randomized controlled trial. *Anesth Analg.* 2019;129(1):155-61.
2. Oh TT, Ikhsan M, Tan KK et al. A novel approach to neuraxial anesthesia: application of an automated ultrasound spinal landmark identification. *BMC anesthiol.* 2019; 19:1-8.
3. Vallejo MC. Pre-procedure neuraxial ultrasound in obstetric anesthesia. *J Anesth Perioper Med.* 2018;5(2):85.
4. Arzola C, Mikhael R, Margarido C et al. Spinal ultrasound versus palpation for epidural catheter insertion in labour: a randomised controlled trial. *Eur J Anaesthesiol.*2015;32(7):499-505.
5. Mele M, Bellussi V, Felder L. Analgesia And Anesthesia. In *obstetric Evidence Based Guidelines.* 2022;137-151.
6. Ghosh SM, Madjdpour C, Chin KJ. Ultrasound-guided lumbar central neuraxial block. *Bja Educ.* 2016;16(7):213-20.
7. Narkhede HH, Kane D, Parekh V, Hemantkumar I. A cohort study of anatomical landmark-guided midline versus pre-procedure ultrasound-guided midline technique of spinal anesthesia in elderly patients undergoing orthopedic surgery. *J. anaesthesiol clin pharmacol.* 2019;35(4):522.
8. Perlas A, Chaparro LE, Chin KJ. Lumbar neuraxial ultrasound for spinal and epidural anesthesia: a systematic review and meta-analysis. *Reg Anesth Pain Med.* 2016;41(2):251-60.
9. Tawfik MM, Atallah MM, Elkhaboutly WS et al. Does preprocedural ultrasound increase the first-pass success rate of epidural catheterization before cesarean delivery? A randomized controlled trial. *Anesth Analg.* 2017;124(3):851-56.
10. Creaney M, Mullane D, Casby C et al. Ultrasound to identify the lumbar space in women with impalpable bony landmarks presenting for elective caesarean delivery under spinal anaesthesia: a randomised trial. *Int j obstet anesth.* 2016; 28:12-16.
11. Jain K, Puri A, Taneja R et al. Preprocedural ultrasound as an adjunct to blind conventional

technique for epidural neuraxial blockade in patients undergoing hip or knee joint replacement surgery: A randomised controlled trial. *Indian j anaesth.* 2019;63(11):924.